

Effect of Earthworm Oil on Formation of Collagen Type III during Wound Healing Process in BALB/c Mice

Mohammad Afshar^{1,2}, Mohammadmehdi Hassanzadeh-Taheri^{1,3}, Mahmood Zardast⁴, Zahra Naderi¹

¹ Department of Anatomy, Faculty of Medicine, Birjand University of Medical Sciences, Birjand, Iran

² Medical Toxicology Research Center, Mashhad University of Medical Sciences, Mashhad, Iran

³ Birjand Cellular and Molecular Research Center, University of Medical Sciences, Birjand, Iran

⁴ Department of Pathology, Birjand University of Medical Sciences, Birjand, Iran

Corresponding author: Zahra Naderi, Department of Anatomy, Faculty of Medicine, Birjand University of Medical Sciences, Birjand, Iran; Email: zahra.naderi1993@gmail.com; Tel.: +98-5154225023

Received: 20 Dec 2020 ♦ **Accepted:** 15 Apr 2021 ♦ **Published:** 30 Apr 2022

Citation: Afshar M, Hassanzadeh-Taheri M, Zardast M, Naderi Z. Effect of earthworm oil on formation of collagen type III during wound healing process in BALB/c mice. Folia Med (Plovdiv) 2022;64(2):267-274. doi: 10.3897/folmed.64.e62272.

Abstract

Introduction: *Eisenia fetida* is a species of earthworm. The oil extracted from this species has been found to have antimicrobial and antioxidant characteristics as well as omega-3, omega-6, and omega-9 fatty acids in its contents. The regenerative properties of this compound are very impressive.

Aim: This study aimed to evaluate the effect of earthworm oil on wound healing based on collagen type III formation in the BALB/c mice.

Materials and methods: The present experimental study was conducted in Birjand, Iran, in 2019. Forty-eight male adults BALB/c mice were divided into 4 groups (12 mice in each group). The intervention group received earthworm oil, the negative and positive control groups received sesame oil and 1% nitrofurazone cream, respectively, whereas the sham group received no treatment at all. A full-thickness excision wound with a 5-mm disposable surgical punch was made on the dorsal skin of all mice after anesthesia. The wounds in groups 1, 2, and 3 were dressed twice a day. At days 4, 7, 10, and 14 after wounding, excisional biopsy was performed and the sample was examined histologically and immunohistochemically using the ImageJ software. Data were analysed by ANOVA and Tukey tests using SPSS software version 22.

Results: In the tissue samples treated with earthworm oil, the number of fibroblast cells and granulation tissue formation and epithelialization significantly increased; the thickness of type III collagen fibers in this group predominantly increased in comparison to other control groups.

Conclusions: This study has demonstrated that the earthworm oil has a positive effect on the wound healing process, especially by promoting the collagen synthesis.

Keywords

collagen formation, earthworm oil, mice, wound healing

INTRODUCTION

A wound is a tissue injury that might be formed due to various factors such as trauma, burns, surgery, and other destructive events. Wound healing can be considered as a dynamic response to injury that is complex and regular and involves interaction among different types of cells, growth factors, and structural proteins.^[1] Annually, chronic wounds affect 6.5 million patients in the United States, with an estimated cost of over \$25 million.^[2] Many factors, including the blood flow of the wound area, the presence of foreign microorganisms, age, and poor nutrition status, can affect the speed of wound healing. Wound healing is a physiological response to the injured skin. It consists of three complex interactive phases: 1) hemostasis – inflammation phase that starts immediately after injury with the launch of hemostatic mechanisms to stop bleeding immediately and migration of inflammatory cells to injured tissue, 2) proliferation phase in which many important events are formed such as the production of collagens, proteoglycan and fibronectin for the formation of extracellular matrix (ECM), new epithelium and angiogenesis^[3], and 3) remodelling phase in which the ECM is organized to produce new functional tissue and mature collagen fibres^[4]. However, the fibroblasts producing the matrix and collagen fibers are the dominant cells in the second stage and are responsible for the synthesis of collagen types. The two dominant types of collagen in wound repair are collagen I and III. Type III collagen is fibrillar-forming collagen that plays some important roles in fibrillogenesis and determines the fibril diameter of collagen I.^[3] It has been reported that accelerating the wound healing process is an important part of the field of healing.^[5]

Nowadays, there is a tendency to use traditional drugs to heal wounds as they are known to be more cost-effective and have fewer side effects in comparison with the chemical drugs used for the purpose.^[5] However, one of the challenges in medical research is how a traditional compound can be made to be useful.^[5,6] Recently, essential oils have been studied and used by the pharmaceutical and food industries because these compounds have been shown to have a variety of therapeutic effects.^[7,8] Earthworms have been used in the traditional medicine of many countries such as Iran, China, Japan, and Indonesia for many therapeutic purposes and have been also known in eastern medicine as anti-inflammatory, analgesic, and antipyretic agents.^[9]

The healing property of the earthworm is very impressive. In Iran, earthworm oil is extracted from the species *Eisenia fetida* which contains omega-3, omega-6, and omega-9 fatty acids.^[10] The inflammatory impacts of earthworm oil result from the omega fatty acids which are components of the earthworm oil.^[11]

The alcoholic extract of the worm also has a strong antimicrobial activity.^[10] Studies have shown that the macromolecular mixture with glycoprotein 90 (G90) extracted from earthworms has antibacterial and antioxidants effects.^[12] On the other hand, the anti-inflammatory and

angiogenic effects of omega-3 fatty acids have been confirmed by many studies.^[10] There are also lymphokines in the body of these worms which with their fibrinolytic effects can be involved in further developing the blood supply of the organs.^[8] Hence, this oil may modify many of the potential mechanisms involved in wound healing and improve it.^[13]

To date, only few studies have focused on finding the wound healing effects of this oil.

AIM

Therefore, the present study was designed to examine the healing effect of earthworm oil based on collagen type III formation in the wounds identified in the skin of BALB/c mice.

MATERIALS AND METHODS

Methods

Animals

This experimental study was performed on 48 adult male BALB/C mice (25±5 g), which were provided by the Experimental Medical Research Center of Birjand University of Medical Sciences (Ethical Code: IR.BUMS.REC.1397.003). The animals were housed in clean individual cages (12:12 hour light/dark cycle, at a temperature of 22°–24°C) and provided free access to standard food and water.

Preparing earthworm oil

Eisenia fetida (Annelida, Lumbricidae) was purchased from an earthworm breeding farm in Mashhad (Iran). The species of the earthworm was identified by a zoologist at Ferdowsi University (Mashhad, Iran). The worms were washed with tap water to remove the soil particles from the bodies of earthworms. They were then soaked in normal saline for 24 hours to clean the earthworm gut. After drying the worms with an incubator, 500 grams of *Eisenia fetida* powder was mixed in a litre of sesame oil, and then exposed to sunlight for 40 days.

Excisional dermal wound technique

The mice were first anesthetized with intraperitoneal injection of ketamine hydrochloride (70 mg/kg) and xylazine (13.4 mg/kg), then the skin on the mice backs was shaved and two symmetrical full-thickness excisional wounds were created beside the midline (at least 2 cm apart) using 5 disposable surgical punches.^[14] The mice were randomly divided into 4 groups (n=12). The intervention group was treated with earthworm oil (group 1), the negative control

group received sesame oil (group 2), the positive control group received nitrofurazone 0.2% (group 3)^[7] and the sham group received no treatment (group 4). The animals received topical treatment twice a day at a 12-h interval (at 8:00 a.m. and 8:00 p.m.)^[7] for 14 consecutive days from baseline (day 0, the day the wound was made). During the study, if a mouse had a skin infection, it was discarded from the study. Digital imaging studies of the wound was performed (on days 4, 7, 10, and 14) using a digital camera (Mavica FD91, Sony). On days 4, 7, 10, and 14 post-wounding, three mice of each group were sacrificed and the excisional wound areas were removed for routine histological and immunohistochemical studies.

Histopathological analysis

Biopsy specimens were obtained from the wound area and fixed in formalin 10% (48 hours), then the samples were prepared for tissue processing and were finally serially sectioned (5 μ m) using a microtome. Sections (n=10) from each group were stained with H&E, also specific stainings including Masson's trichrome stain and immunohistochemistry (IHC) were performed to assess the morphological details and the density of collagen types I and III.^[15] For each specimen, epidermal parameters (i.e. re-epithelization) and dermal parameters including inflammatory cells (i.e. lymphocytes and neutrophils), granulation, and collagen synthesis were evaluated by ImageJ software. To perform IHC, 5- μ m sections (n=20) were placed on charged slides and rehydrated. The sections were washed in 0.1 M phosphate-buffered saline (PBS) (pH=7.4). Endogenous peroxidase activity was blocked by 0.3% (v/v) H₂O₂. The samples were then incubated in PBS (0.01 M) with Triton X100 (0.025%) for 10 min at room temperature. Samples were incubated in goat serum 10% with 1% BSA in 0.01 M PBS for 30 min. Primary antibody (Abcam Ab7778 Anti-Collagen III Antibody) with concentration (1.55% BSA1%) was poured on the samples for 12 h (overnight). Slides were washed with PBS containing Triton X100 (0.025%) in two successive 5-min steps. Secondary antibody (Abcam Ab7090 Goat Anti-Rabbit IgG H&L (HRP)) was diluted to 1.000% BSA1% and incubated on the samples at room temperature for 2 hours. PBS containing Triton X100 (0.025%) was used for 5 min to wash on the slides. A mixture of two solutions, DAB (0.03%, Sigma Aldrich) of and H₂O₂ (0.01%) dissolved in PBS (0.01 M), was added to the samples for 30 min. Then, slides were washed with distilled water (3 min) to eliminate DAB from non-specific locations. Mayer hematoxylin staining (for 10 seconds) was the next step. After final washing, the slides were dehydrated and mounted. Images were obtained using an Olympus SZX microscope fitted with Pixera digital camera.

Statistical analysis

Data were analysed using SPSS statistical software (version 22). One-way ANOVA test was used to intergroup compar-

isons and Tukey test was used to compare data obtained from all groups of the study. The quantitative data were expressed as mean \pm standard deviation (SD). Results with $p < 0.05$ were considered statistically significant.

RESULTS

Histopathological analysis

All data related to the inflammatory cells, granulation area, fibroblast, and collagenisation are shown in **Table 1**. On day 4 of the study, the average number of inflammatory cells in the intervention group (earthworm oil) was significantly less than that number in the other control groups (groups 2, 3, 4). During the wound healing, there was no evidence of proliferation of fibroblastic cells, granulation, angiogenesis, and synthesis of collagen fibers on the mentioned day ($p > 0.05$). Interestingly, the findings 7 days after wounding showed that the number of inflammatory cells (mononuclear and polymorph) significantly decreased in the mice treated with earthworm oil compared to those treated with nitrofurazone, sesame oil, and the sham group (groups 2, 3, 4) ($p = 0.001$) (**Table 1**). Also, a significant increase was observed in the treated group with earthworm compared to other control groups (groups 2, 3, 4) when the mean number of fibroblasts was analysed ($p = 0$). Furthermore, the rate of granulation tissue formation and angiogenesis were significantly higher in the earthworm oil-treated group than in the control groups (groups 2, 3, 4) ($p = 0.00$). On the other hand, on day 10, the average number of inflammatory cells significantly decreased in the earthworm oil-treated group compared to the nitrofurazone-treated, the sesame oil-treated, and the control groups ($p = 0$), while the mean number of fibroblasts, the granulation area, and epithelization were found to be greatly increased in the earthworm oil-treated group compared to the other groups (groups 2, 3, 4) ($p = 0$, $p = 0.042$, and $p = 0$, respectively) (**Fig. 1**). Also, in the nitrofurazone-treated group, the mean number of whole fibroblasts and granulation area showed a significant difference in comparison with the control sham group (group 4) ($p = 0.009$, $p = 0.001$). The overall average collagen fibers density in the earthworm oil group was significantly higher than in the other groups (groups 2, 3, 4) ($p = 0$). The density of collagen fibers in the nitrofurazone-treated group also showed a significant increase compared to the sham and sesame oil groups (groups 3, 4) ($p = 0$). The score of type III collagen synthesis in two groups – the earthworm oil and the nitrofurazone-treated groups – was higher than that of the negative and sham control groups (groups 3, 4) ($p = 0$, $p = 0.001$) (**Fig. 2**). At the end of day 14, in the group treated with earthworm oil, the mean number of fibroblast cells significantly increased compared to the sesame oil and nitrofurazone groups (groups 2, 3) ($p = 0.005$). Also, in the nitrofurazone group, the number of fibroblast cells increased compared to the negative and sham control groups

(groups 3, 4) ($p=0.012$) (**Table 1**). Moreover, the granulation area was significantly increased in the group treated with earthworm oil compared to the sham group (group 4) ($p=0.00$), and in the nitrofurazone-treated group compared to the other groups (groups 3, 4) ($p=0$) (**Fig. 1**). Also, the mean total density of collagen fibers was significantly higher in the earthworm oil group than in the sham, the nitrofurazone, and the sesame oil groups (groups 2, 3, 4) ($p=0$). In this regard, collagen fibers density was significantly increased in the nitrofurazone group when compared with

the other control groups (groups 3, 4) ($p=0.001$). In the earthworm oil-treated group, the score of collagen type III synthesis and the mean of epithelialization was higher than in the other groups (groups 2, 3, 4) ($p=0$, $p=0$) (**Table 2**).

DISCUSSION

Earthworm oil has been reported to have several biological activities including anti-oxidative, anti-microbial, and an-

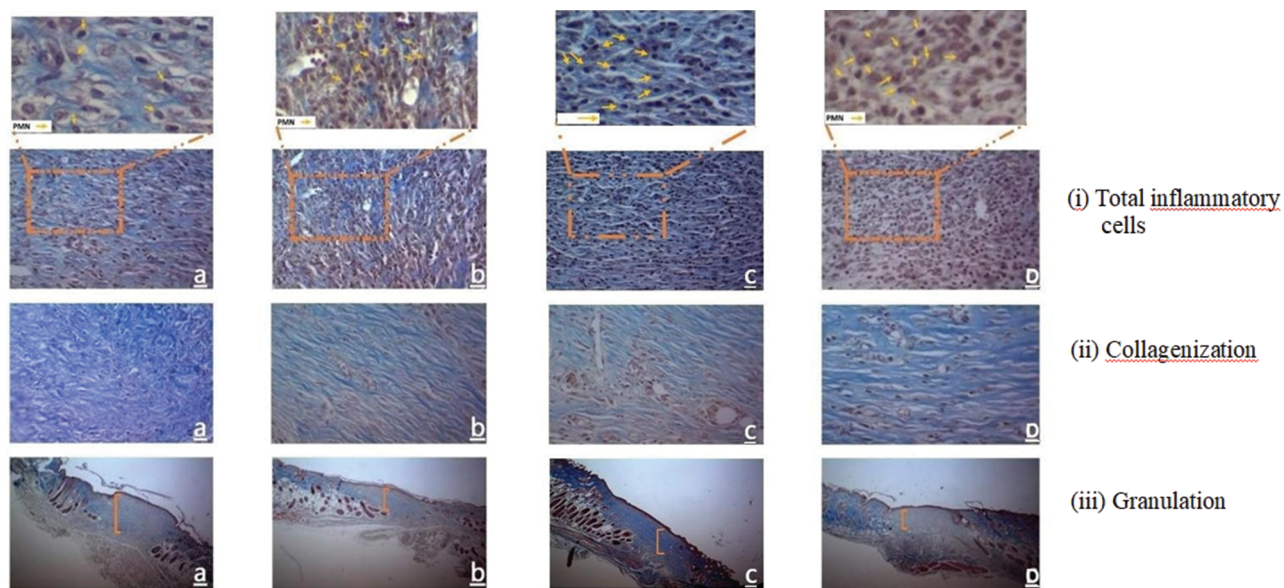


Figure 1. (i) Total inflammatory cells infiltration in **a.** (earthworm oil), **b.** (nit), **c.** (sesame oil), and **d.** (sham), Trichrome staining, magnification $\times 400$ in $257/55 \times 334/65 \mu\text{m}^2$ at day 10; (ii) Collagenization in **a.** (earthworm oil), **b.** (nit), **c.** (sesame oil), **d.** (sham), Trichrome staining, magnification $\times 400$ in $257/55 \times 334/65 \mu\text{m}^2$ at day 10; (iii) The area of granulation in **a.** (earthworm oil), **b.** (nit), **c.** (sesame oil), **d.** (sham), Trichrome staining, magnification $\times 400$ in $3204/12 \times 2401/34 \mu\text{m}^2$ at day 10.

Table 1. The effect of earthworm oil on dermal and epidermal parameters in wound healing

	Day	Earthworm oil	Nitrofurazone	Sesame oil	Sham	P-value ¹
Inflammation	4	22.00 \pm 4.83 ^{a,b}	29.50 \pm 3.89 ^a	32.7 \pm 3.8	34.8 \pm 7.08	<0.001
	7	30.20 \pm 4.13 ^{a,b}	41.4 \pm 2.36 ^a	47.8 \pm 5.99	50.60 \pm 4.19	<0.001
	10	18.9 \pm 3.51 ^{a,b}	24.4 \pm 4.24 ^a	31.5 \pm 3.34	34.4 \pm 3.7	<0.001
Granulation	7	1883603.474 \pm 312649.66 ^{a,b}	1077241.91 \pm 551699.52	1036133.59 \pm 201206.95	120902.47 \pm 375595.26	0.002
	10	1688831.86 \pm 709933.136 ^a	211386.421 \pm 605012.67 ^a	1767479.59 \pm 339268.36	925183.86 \pm 155969.78	0.042
	14	1302440.497 ^a \pm 231688.6405	1438549.87 \pm 191935.661 ^a	1239835.689 \pm 237112.4971	742293.2522 \pm 131162.5436	<0.001
Collagenization	10	0.33 \pm 0.016 ^{a,b}	0.29470 \pm 0.16	0.25570 \pm 0.12	0.24319 \pm 0.01	<0.001
	14	0.5871 \pm 0.030 ^{a,b}	0.49503 \pm 0.029 ^a	0.5387 \pm 0.033	0.46570 \pm 0.21	<0.001
Fibroblast	7	27.9 \pm 2.02 ^{a,b}	21.30 \pm 2.26	22.1 \pm 3.95	19.50 \pm 1.58	<0.001
	10	50.8 \pm 2.52 ^{a,b}	42.6 \pm 4.14 ^a	36 \pm 4.15	36.5 \pm 4.90	<0.001
	14	34.80 \pm 4.82 ^a	30.10 \pm 2.42 ^a	25.90 \pm 6.04	20.20 \pm 3.25	<0.001

P-value¹: ^a: compared with the sham control group; ^b: compared with the nitrofurazone group

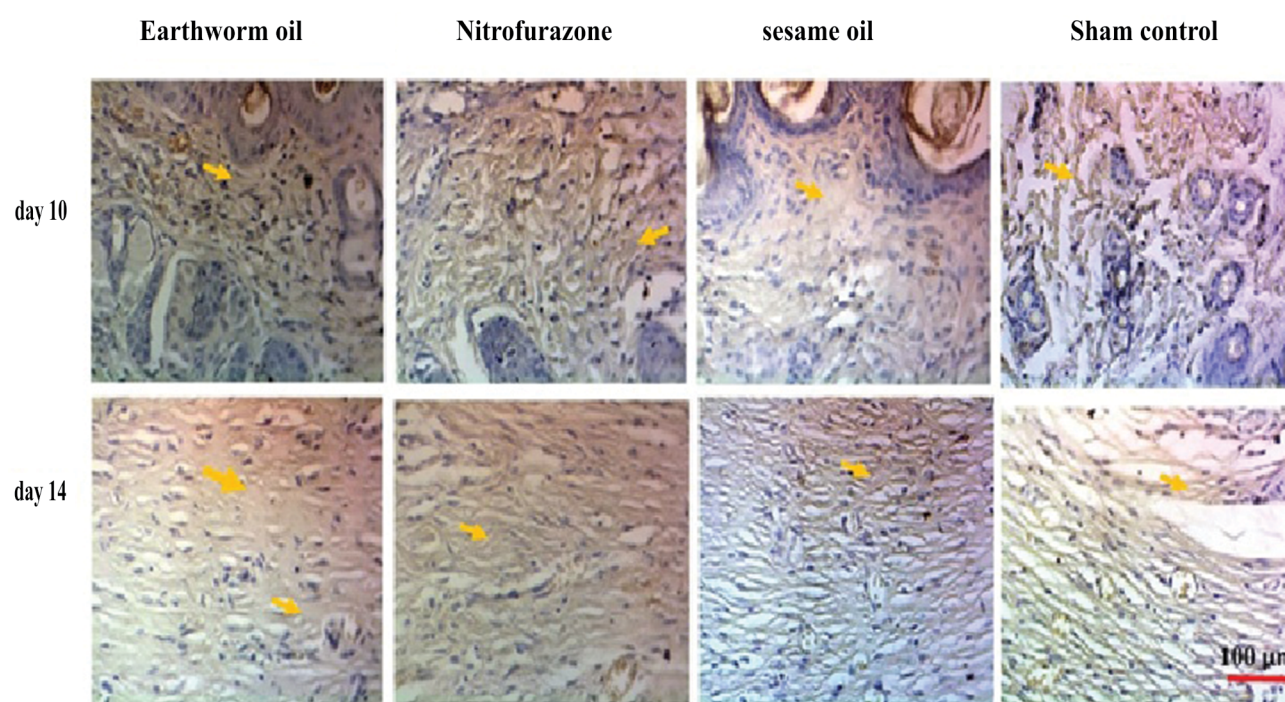


Figure 2. Comparative collagen type III images at days 10 and 14: samples in the studied groups. Magnification $\times 400$ in $257/55 \times 334/65 \mu\text{m}^2$ (IHC staining).

Table 2. The effect of earthworm oil on type III collagen synthesis in wound healing

Collagenization	Day	Earthworm oil	Nitrofurazone	Sesame oil	Sham	P-value ¹
Collagen type III	10	$0.22516 \pm 0.018^{a,b}$	0.17864 ± 0.020^a	0.15977 ± 0.019	0.14342 ± 0.029	<0.001
	14	$0.17334 \pm 0.023^{a,b}$	0.16265 ± 0.19^a	0.13128 ± 0.11	0.12476 ± 0.02	<0.001

^a: compared with the sham control group; ^b: compared with the nitrofurazone group

ti-coagulative functions. Also, the benefits it has for tissue regeneration and wound healing have been recently proved. The results of our study showed that earthworm oil exerts positive effects on different stages of wound healing, especially on the process of collagen type III formation. Wound healing is a natural response of injured skins that consists of three interactive phases including inflammation, proliferation, and remodelling.^[3] The inflammatory phase starts immediately after injury and is characterized by the influx of two important leukocytes, lymphocytes, and neutrophils.^[16] In the present study, the results obtained in days 4, 7, and 10 showed that treatment with earthworm oil could decrease inflammation and infiltration of inflammatory cells. Mathur et al. showed that petroleum ether fraction of earthworm extract had a comparable anti-inflammatory effect to that of aspirin.^[17] In another study, the anti-inflammatory activity of *Eutyphoeus gammiei* (a type of earthworm species) was assessed in the carrageenan-induced animal model and the results of this study confirmed the previous study.^[18] Moreover, Balamurugan et al. reported similar results in their study.^[19]

On the other hand, the proliferative or repair phase is

characterized by granulation tissue formation, angiogenesis, wound contraction, and epithelialization.^[3] Fibroblasts, as the main cell type in granulation tissue formation, are involved in the proliferation process and produce matrix components, including hyaluronan, fibronectin, proteoglycans, and procollagen (types I and III).^[3] The results of days 7, 10, and 14 of our study revealed that treatment with earthworm oil could increase the mean number of fibroblast cells and the thickness of the granulation tissue. Yang et al. investigated the therapeutic effects of earthworm extract (G-90'), which was separated from the head tissue of *Eisenia fetida*, on the wound healing process in vitro and in vivo; their results showed the bioactive proteins (ES2) in G-90' enhanced the proliferative phase in the acute wound healing process.^[20] Their results have been considered as a new concept in using such a natural material in wound healing. Furthermore, Grdiša et al. investigated the efficacy of a glycolipoprotein tissue homogenate extracted from *Eisenia fetida* (G-90) to activate signal transduction pathways, which are involved in wound healing.^[21] Their results showed that treatment with G-90 could stimulate the synthesis of the epidermal growth factor (EGF, 10-fold

elevations) and fibroblast growth factor (FGF, 5-fold elevations) in the wound compared to the healthy skin.^[21] EGF and FGF by increasing the proliferation of epithelial cells and promoting angiogenesis and growth of fibroblast cells, respectively, could promote the rate of wound healing.^[21] However, it seems that one of the causes of fibroblast proliferation is related to the FGF level. We strongly suggest that the levels of FGF and EGF should be investigated in future studies.

The final step of wound healing is the maturation phase. In this stage, the granulation tissue is converted into mature connective tissue regeneration.^[3] The normal skin contains about 80% type I collagen and 20% type III collagen. Collagen type III, which is involved in fibrillogenesis and determination of the fibril diameter of collagen I, is made by myofibroblasts during the early stages of granulation tissue formation.^[3] Moreover, in the early stages of healing, the expression of collagen type III increases relative to collagen I, resulting in an increased ratio between the two collagen subtypes from 20% up to 50% collagen III, but during maturation of the scar, this ratio backs to the normal levels.^[3]

In the present study, on days 10 and 14, treatment with earthworm oil increased the density of collagen fibers. Heydari et al., by evaluating the comparative effects of earthworm extract and phenytoin sodium on suture wound healing in Goldfish (*Carassius auratus*), reported that the earthworm extract could produce better collagen fibers, increase the formation of granulation tissues, angiogenesis, and fibroblast proliferation, and also could decrease lipid peroxidation (LPO) in fish serum.^[22] Wound contraction has been considered as a good factor for evaluating the rate of wound healing.^[3] The contraction of the wound is done by differentiated myofibroblasts from migrating fibroblasts in granulation tissue.^[3] Differentiated myofibroblasts lead to the formation of pseudopodia, which are involved in attaching to fibronectin and collagen in the ECM.^[23] The process of wound contraction is initiated by this attachment.^[23]

The results of this study showed that treatment with earthworm oil led to complete re-epithelization of the epidermal layer with a higher percentage of wound contraction. Earthworm oil contains omega-3, omega-6, and omega-9 fatty acids; hence, it seems that these fatty acids, through their anti-inflammatory and angiogenic properties, could modify many of the potential mechanisms involved in reducing the diameter of the wound and finally improve wound healing. Cardoso et al. showed that omega-6 had better effects on wound healing in mice compared to omega-3 and omega-9.^[24] On the other hand, it has been reported that omega-6 (30 μ M treatment with omega-6) could decrease cyclooxygenase-2 (COX-2) level and also induce the expression of collagen type III. Furthermore, this study also showed that omega-3 fatty acid is involved in the early closure of open wounds, but not as much as the oleic acid.^[24,25] Administration of the COX-2 inhibitor delayed re-epithelialization in the early phase of wound healing and also inhibited angiogenesis.^[25]

CONCLUSIONS

The study presented the results about the role of earthworm oil in the wound healing process by a significant proliferation of fibroblast and collagen type III synthesis.

Conflict of Interests

The authors declare that there is no conflict of interests.

Acknowledgments

The current study was extracted from an MSc thesis (455454) in anatomical science by Zahra Naderi at Birjand University of Medical Sciences, Birjand, Iran.

REFERENCES

1. Alahtavakoli M, Vazirinejad R, AnsariJaberi A, et al. Effect of *Teucrium polium* extract on skin wound healing in rat. *Hormozgan Medical Journal* 2012; 16:17–24.
2. Budovsky A, Yarmolinsky L, Ben-Shabat S. Effect of medicinal plants on wound healing. *Wound Repair Regen* 2015; 23:171–83.
3. Bhat PB, Hegde S, Upadhyay V, et al. Evaluation of wound healing property of *Caesalpinia mimosoides* Lam. *J Ethnopharmacol* 2016; 193:712–24.
4. Robins SP, Milne G, Duncan A, et al. Increased skin collagen extractability and proportions of collagen type III are not normalized after 6 months healing of human excisional wounds. *J Invest Dermatol* 2003; 121:267–72.
5. Barreto RS, Albuquerque-Júnior RL, Araújo AA, et al. A systematic review of the wound-healing effects of monoterpenes and iridoid derivatives. *Molecules* 2014; 19:846–62.
6. Lodhi S, Pawar RS, Jain AP, et al. Wound healing potential of *Tephrosia purpurea* (Linn.) Pers. in rats. *J Ethnopharmacol* 2006; 108:204–10.
7. Afshar M, Ghaderi R, Zardast M, et al. Effects of topical emu oil on burn wounds in the skin of Balb/c mice. *Dermatol Res Prac* 2016; 2016.
8. Wang KY, Tull L, Cooper E, et al. Recombinant protein production of earthworm lumbrokinase for potential antithrombotic application. *Evid Based Complement Alternat Med* 2013; 2013.
9. Balamurugan M, Parthasarathi K, Cooper E, et al. Earthworm paste (*Lampito mauritii*, Kinberg) alters inflammatory, oxidative, haematological and serum biochemical indices of inflamed rat. *Eur Rev Med Pharmacol Sci* 2007; 11:77.
10. Cooper EL, Ru B, Weng N. Earthworms: sources of antimicrobial and anticancer molecules. *Complementary and Alternative Approaches to Biomedicine* 2004:359–89.
11. Gutiérrez S, Svahn SL, Johansson ME. Effects of omega-3 fatty acids on immune cells. *Int J Mol Sci* 2019; 20:5028.
12. Shi Y, Xu X, Chen J, et al. Antioxidant gene expression and metabolic responses of earthworms (*Eisenia fetida*) after exposure to various concentrations of hexabromocyclododecane. *Environ Pollut* 2018; 232:245–51.

13. Khaksari M, Sajadi M. The effect of fish oil diet on wound healing in diabetic rats. *Physiol Pharmacol* 2001; 3:181–92.
14. Wang X, Ge J, Tredget EE, et al. The mouse excisional wound splinting model, including applications for stem cell transplantation. *Nat Protoc* 2013; 8:302.
15. Sen CK, Khanna S, Venojarvi M, et al. Copper-induced vascular endothelial growth factor expression and wound healing. *Am J Physiol Heart Circ Physiol* 2002; 282:H1821–H7.
16. Majewska I, Gendaszewska-Darmach E. Proangiogenic activity of plant extracts in accelerating wound healing – a new face of old phytomedicines. *Acta Biochimica Polonica* 2011; 58(4):449–60.
17. Mathur A, Verma SK, Singh SK, et al. Anti-inflammatory activity of earthworm extracts. *Int J Pharm Sci Res* 2011; 2:278.
18. Madhusudan D, Ranjib G, Deepjyoti B, et al. Anti-inflammatory effect of extract of earthworm *Eutyphoeus Gammiei* from Tripura, north eastern India. *Int J Pharm Biol Sci* 2018; 8:622–7.
19. Balamurugan M, Parthasarathi K, Cooper E, et al. Anti-inflammatory and anti-pyretic activities of earthworm extract – *Lampito mauritii* (Kinberg). *J Ethnopharmacol* 2009; 121:330–2.
20. Yang Y, Hu H, Wang W, et al. The identification of functional proteins from amputated lumbricus *Eisenia fetida* on the wound healing process. *Biomed Pharmacother* 2017; 95:1469–78.
21. Grdiša M, Popović M, Hrženjak T. Stimulation of growth factor synthesis in skin wounds using tissue extract (G-90) from the earthworm *Eisenia foetida*. *Cell Biochem Funct* 2004; 22:373–8.
22. Heydari S, Arabi M, Nematollahi A, et al. Comparative effects of earthworm extract and phenytion sodium on suture wound healing in goldfish (*Carassius auratus*). *J Cell Tissue* 2015; 5(4):361–8.
23. Xue M, Jackson CJ. Extracellular matrix reorganization during wound healing and its impact on abnormal scarring. *Adv Wound Care* 2015; 4:119–36.
24. Ribeiro Barros Cardoso C, Aparecida Souza M, Amália Vieira Ferro E, et al. Influence of topical administration of n-3 and n-6 essential and n-9 nonessential fatty acids on the healing of cutaneous wounds. *Wound Repair Regen* 2004; 12(2):235–43.
25. Cardoso CR, Favoreto Jr S, Oliveira LL, et al. Oleic acid modulation of the immune response in wound healing: a new approach for skin repair. *Immunobiology* 2011; 216(3):409–15.

Влияние масла дождевых червей на образование коллагена III типа в процессе заживления ран у мышей BALB/c

Мохамед Афшар^{1,2}, Мохамедмехди Хасансадех-Тахери^{1,3}, Махмуд Зардаст⁴, Захра Надери¹

¹ Кафедра анатомии, Медицинский факультет, Университет медицинских наук Бирджанда, Бирджанд, Иран

² Исследовательский центр медицинской токсикологии, Университет медицинских наук Маишада, Маишад, Иран

³ Центр клеточных и молекулярных исследований Бирджанда, Университет медицинских наук, Бирджанд, Иран

⁴ Кафедра патологии, Университет медицинских наук Бирджанда, Бирджанд, Иран

Адрес для корреспонденции: Захра Надери, Кафедра анатомии, Медицинский факультет, Университет медицинских наук Бирджанда, Бирджанд, Иран; Email: zahra.naderi1993@gmail.com; Тел.: +98-5154225023

Дата получения: 20 декабря 2020 ♦ **Дата приемки:** 15 апреля 2021 ♦ **Дата публикации:** 30 апреля 2022

Образец цитирования: Afshar M, Hassanzadeh-Taheri M, Zardast M, Naderi Z. Effect of earthworm oil on formation of collagen type III during wound healing process in BALB/c mice. Folia Med (Plovdiv) 2022;64(2):267-274. doi: 10.3897/folmed.64.e62272.

Резюме

Введение: *Eisenia fetida* — вид дождевых червей. Было обнаружено, что масло, извлечённое из этого вида, обладает антимикробными и антиоксидантными свойствами, а также содержит жирные кислоты омега-3, омега-6 и омега-9. Регенеративные свойства этого соединения очень впечатляют.

Цель: Это исследование было направлено на оценку влияния масла дождевых червей на заживление ран на основе образования коллагена III типа у мышей BALB/c.

Материалы и методы: Настоящее экспериментальное исследование было проведено в Бирджанде, Иран, в 2019 г. Сорок восемь взрослых самцов мышей BALB/c были разделены на 4 группы (по 12 мышей в каждой группе). Группа, подвергнутая воздействию получала масло дождевого червя, группы отрицательного и положительного контроля получали кунжутное масло и 1% крем нитрофуразона, соответственно, в то время как группа имитации не получала ничего. На коже спины всех мышей после анестезии наносили полнослойную иссечённую рану одноразовым хирургическим щипцом диаметром 5 мм. Раны в группах 1, 2 и 3 перевязывали два раза в сутки. На 4, 7, 10 и 14 сутки после ранения выполняли эксцизионную биопсию и гистологически и иммуногистохимически исследовали образец с помощью программы ImageJ. Данные анализировали с помощью тестов ANOVA и Tukey с использованием программного обеспечения SPSS версии 22.

Результаты: В образцах тканей, обработанных маслом дождевых червей, значительно увеличилось количество клеток фибробластов, образование и эпителизация грануляционной ткани; толщина коллагеновых волокон III типа в этой группе преимущественно увеличивалась по сравнению с другими контрольными группами.

Заключение: Это исследование показало, что масло дождевых червей оказывает положительное влияние на процесс заживления ран, особенно за счёт стимулирования синтеза коллагена.

Ключевые слова

образование коллагена, масло дождевых червей, мыши, заживление ран
