



# First Etiologically Confirmed Cases of *Mycobacterium Marinum* Infection in Bulgaria

Elizabeta Bachiyska, Yuliana Atanasova, Ana Baykova, Stanislava Yordanova, Yana Todorova

National Reference Laboratory of Tuberculosis, Sofia, Bulgaria, National Center of Infectious and Parasitic Diseases, Sofia, Bulgaria

**Corresponding author:** Elizabeta Bachiyska, National Reference Laboratory of Tuberculosis, 44A Stoletov Blvd., 1233 Sofia, Bulgaria; E-mail: elizabet-batchiiska@abv.bg; Tel.: +359 2 944 64 45

**Received:** 10 Oct 2019 ♦ **Accepted:** 19 Dec 2019 ♦ **Published:** 30 June 2020

**Citation:** Bachiyska E, Atanasova Y, Baykova A, Yordanova S, Todorova Y. First etiologically confirmed cases of *Mycobacterium marinum* infection in Bulgaria. *Folia Med (Plovdiv)* 2020;62(2):398-402. doi: 10.3897/folmed.62.e47220.

## Abstract

This study aimed to describe the first two microbiologically confirmed cases of cutaneous and soft tissue *Mycobacterium marinum* infection in Bulgaria. The isolation of the Nontuberculous Mycobacteria (NTM) strains and their species identification was performed at NRL TB, NCIPD using specific media and cultivation conditions, and PCR based Line Probe Assay (LPA) from the positive cultures. The two patients had closely related jobs to fishes and water reservoirs and both of them had a similar clinical manifestation of *M. marinum* infection known as “swimming pool” or “fish tank” granuloma. The prolonged specific treatment with at least two-drug combination of rifampicin plus ethambutol and some complications were a big challenge for clinicians as well as the patients.

## Keywords

LPA, mycobacteriosis, *Mycobacterium marinum* infection, NTM

## INTRODUCTION

*Mycobacterium marinum* is a slow-growing NTM also known as atypical mycobacterium or environmental mycobacterium or MOTT (Mycobacterium Other Than Tuberculosis), and belongs to the same genus as the pathogens causing tuberculosis and leprosy.<sup>1,2</sup> *M. marinum* is found around the world in nondisinfected salt- and freshwater reservoirs such as swimming pools and fish tanks, hence the name of the condition: “swimming pool” or “fish tank” granuloma.<sup>3</sup> The mycobacteriosis involves usually fingers of the right hand – most people are right-handed and they fish, clean fish tanks or do some other aquatic activities using the right hand. Infection occurs most commonly at sites of small skin wounds or abrasions where bacteria enter. Signs of disease involve localized painless skin lesions, single or multiple nodules or ulcers. Less commonly *M. marinum* can spread in the body and cause joint or bone infections.<sup>4</sup> Lethal outcome occurs on very rare occasions, most often in immunocompromised persons.<sup>5</sup> *M. marinum* infections

as part of NTM diseases are not notifiable in most European countries and the overall epidemiological situation in European Union (EU) and European Economic Area (EEA) is largely unknown. There is no evidence that *M. marinum* infection can be spread from person to person. In some Balkan countries neighbouring to Bulgaria data have been published on microbiological documentation on *M. marinum*. Between 2005 and 2011, isolation of 5 strains of *M. marinum* was reported in Greece, isolation of 6 strains was reported in Slovenia for the period 2000-2010, and no such strain was isolated in Croatia between 2008 and 2010.<sup>6</sup> In Bulgaria there were no cases of isolated *M. marinum* between 2009 and 2013.<sup>7</sup>

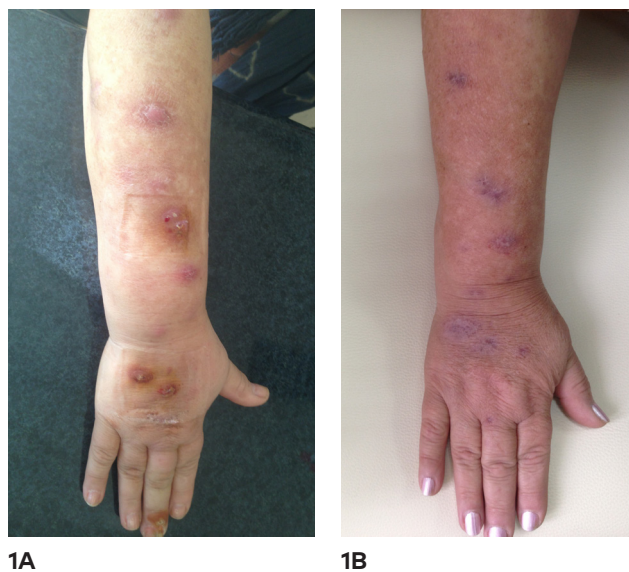
## MATERIALS AND METHODS

In both clinically described cases herein reported we examined skin samples and pus from the wound site. A smear microscopy for AFB (Ziel-Neelsen) was performed and

cultivating on specific media – solid medium (Löwenstein-Jensen) and liquid media (MGIT) at lower temperature – room temperature, i.e. 25-28°C. For species identification of *M. marinum* we used Geno Type Mycobacterium Common Mycobacteria (CM) (HAIN Lifescience, Nehren, Germany), based on DNA strip technology for LPA: DNA amplification of 23S rRNA gene, reverse hybridization and immobilization on a membrane strip. PCR diagnosis was supplemented with phenotypic analysis, including examination of grow characteristics, temperature tolerance, and pigmentation of colonies.

## CASE REPORT


The first microbiologically confirmed case of cutaneous *M. marinum* disease was in 2014. A 66-year-old woman presented with 12 small red-violet papules on the dorsum of the right hand and forearm, some of them having progressed to pustules and ulcers, more or less in straight line proximally (Fig. 1A). The patient was immunocompetent and clinically healthy. She was a pet shop owner. A few days after feed stem pricking under the middle finger nail of her right hand she cleaned an ornamental tropical fishes aquarium without using protective gloves. The fishes were bought from Romanian pet shop the previous month.



**Figure 1.** Case 1: 1A) lesions before therapy, 1B) after two months of antimicrobial therapy.

The first skin lesions on the right hand occurred approximately 3 weeks after a local hand injury. The progression from erythematous plaques through papules, pustules and ulcers was painless in the next month (Fig. 1A). The lesion was excised and sent for histological examination. Histology revealed chronic inflammatory granulation tissue and giant cell of the Langhans type. In NRL TB, NCIPD was taken wound secretion with skin sample for microbiological examination. Smear microscopy for AFB was negative.

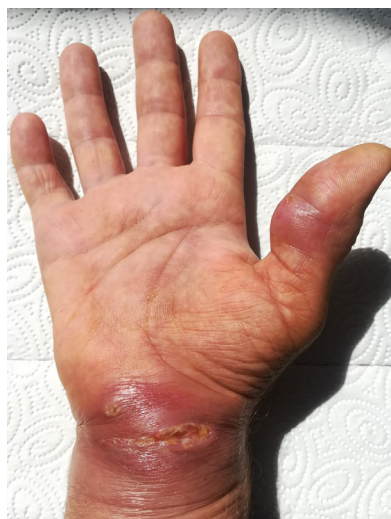Culture at room temperature was positive only on MGIT, 25 days after inoculation (Fig. 2).



**Figure 2.** Case 1: positive culture only on liquid medium (MGIT) at room temperature.


There was no growth on liquid and solid media at 37°C. The cord-factor phenomenon was revealed using Ziel-Neelsen staining from positive MGIT culture. Lowenstein-Jensen was negative the end of 56 days cultivating. Immunochromatographic test (BD MGIT TBc Identification Test) did not show presence of MPT64 antigen in the strain, i.e. it was negative for *M. tuberculosis* complex in a differential diagnosis plan. The subsequent subculture from positive MGIT on Lowenstein-Jensen allowed us to trace the colony morphology, photo reactivity, pigmentation and growth rate. Twenty-eight days after the primary inoculation on MGIT, we identified *M. marinum* by Geno Type Mycobacterium CM using extracted DNA. A specific two-drug therapy with a combination of rifampicin (600 mg/day) and ethambutol (1000 mg/day) for at least 6 months was started after microbiological confirmation and was discontinued at 2 months because of the side effects as joint pain, candidosis, diarrhea and intestinal pain. The treatment continued with symptomatic therapy and the lesions slowly improved after 8 months of therapy (Fig. 1B).

The second microbiologically detected *M. marinum* case occurred at the beginning of 2019 in a 50-year-old male fisher and diver from a small Black sea village near the border between Bulgaria and Turkey. The first clinical signs appeared 2 to 3 weeks after a stab wound on the right hand little finger by a fish fin of belted bonito (*Palamis sarda*). A part of the fish fin remained briefly under the skin of the finger. T-Spot. TB test of the patient was positive. The infection progressed from lesions on the little finger and the thumb to a deep tissue infection of wrist with damage of the tendons, synovial tissue and joint, which resulted in a compromised hand function (Fig. 3). Then the carpal tunnel syndrome occurred and the patient underwent surgery.

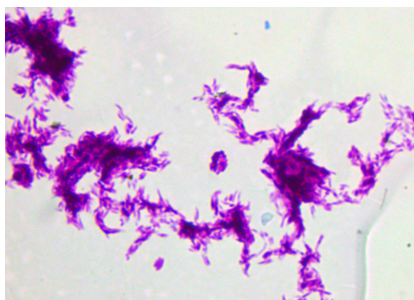


**Figure 3.** Case 2: deep soft tissue *M. marinum* infection of right wrist with carpal tunnel syndrome.

Tissue biopsy sample was sent for culture and histology. Histology was the same as in Case 1. The smear microscopy for AFB was negative. The cultures at room temperature were positive on both liquid and solid media – on MGIT after 14 days from the inoculation and respectively on Löwenstein-Jensen after 54 days (**Fig. 4**). There was no growth on liquid and solid media at 37°C. The “cord-factor” was observed on Ziel-Neelsen staining from positive MGIT culture (**Fig. 5**). We extracted DNA from MGIT and identified *M.*



**Figure 4.** Case 2: positive solid media Löwenstein-Jensen 54 days after inoculation.



**Figure 5.** Case 2: Ziehl-Neelsen staining of positive MGIT after 2 weeks of incubation. “Cording” is present.

*marinum* by Geno Type Mycobacterium CM. A treatment regimen of rifampicin 600 mg/day and ethambutol 1000 mg/day was begun following the etiological confirmation of the diagnosis. The patient rapidly responded to the treatment. But a month later he felt strong pain in the area of the operative wound and had again the symptoms of carpal tunnel syndrome. Redo surgery followed by revision, debridement, desinscizio, excision, decompression and reinsertion. The intra operationem taken samples were microbiologically negative. The two-regimen therapy continued plus clarithromycin 500 mg/day for the next 6 months and the patient's condition slowly improved.

## DISCUSSION

The delay of diagnosis of *M. marinum* infection is common, probably due to the rarity of the infection.<sup>4,8,9</sup> In both cases reported herein, the patients have been consulted by dermatologists, rheumatologists, infectious disease specialists, orthopedists, surgeons, until some of them decided to send biopsies – more often for histology and rarely for microbiology. Usually histology is identical to mycobacteriosis and tuberculosis and then comes into consideration the history with swimming, fishing and other activities related to water tanks or marine life.<sup>9</sup> Of course, the history of *M. marinum* infection is very pivotal, but in our practice we had cases with fishing injuries history but subsequently we identified *M. tuberculosis*. With respect to the immunological tests, except for tuberculosis, they are also positive in *M. marinum*, *M. kansasii*, *M. szulgai*, and *M. riyadhense* mycobacteriosis.<sup>10</sup> In the second case the T-Spot.TB test was positive. The differential diagnosis between tuberculosis and mycobacteriosis should always be taken into consideration given that the treatment for the two diseases is different. For example, two potent drugs used in the intensive phase of tuberculosis such as isoniazide and pyrazinamide are not applicable to the *M. marinum* infection due to innate resistance.<sup>2,11,12</sup> Culture and species identification of *M. marinum* play a crucial role in the further development of the infection. *M. marinum* infections have slow, spontaneous resolution over period of 1 to 6 years.<sup>5,12</sup> Antimicrobial therapy (rifampicin, ethambutol, clarithromycin, trimethoprim/sulfamethoxazole, tetracycline, and some of the quinolones) may be warranted to prevent progression to deep infection. Corticosteroids should be avoided, because of exacerbation of the condition.<sup>5,11</sup> Depending on the extent and severity of *M. marinum* infection, the therapy may continue from several weeks to 18 months.<sup>2,5,11</sup> Deep *M. marinum* infection typically requires both antimicrobial and surgical treatment. Debridement of the necrotic tissues may be necessary. In order to control the infection despite appropriate therapy and related debridement, amputation may be required. *M. marinum* systemic disease is rare and most commonly affects immunocompromised patients.<sup>5,9,11</sup>



## CONCLUSION

*M. marinum* infection is uncommon but not rare. To diagnose the condition the physician should have an appropriate case history and suspicion. The diagnosis should be confirmed by biopsy and subsequent microbiological examination to identify the etiological cause as other etiological agents may also produce identical lesions. Early microbiological diagnosis allows clinicians to use the appropriate therapy. The management of the infection depends on the severity of the infection. A long-term, at least two-drug specific therapy is curative in some superficial cases but surgical debridement is often indicated in extensive and deep infections.

## REFERENCES

1. Euzeby JP 2003. List of bacterial names with standing in nomenclature – Genus *Mycobacterium*. Available from: <http://www.bacterio.cict.fr/m/mycobacterium.html>.
2. Griffith DE, Aksamit T, Brown-Elliott BA, et al. An official AST/IDSA statement: diagnosis, treatment, and prevention of nontuberculous mycobacterial diseases. *Am J Respir Crit Care Med* 2007; 175: 367–416.
3. Lewis FM, Marsh BJ, von Reyn CF. Fish tank exposure and cutaneous infections due to *Mycobacterium marinum*: tuberculin skin testing, treatment, and prevention. *Clin Infect Dis* 2003; 37(3): 390–7.
4. Johnson MG, Stout JE. Twenty-eight cases of *Mycobacterium marinum* infection: retrospective case series and literature review. *Infection* 2015; 43(6):655–62.
5. Rovid Anna. The Center for Food Security and Public Health. *Mycobacteriosis* 2016; Available from: <http://www.cfsph.iastate.edu/DiseaseInfo/factsheets.php>.
6. van der Werf MJ, Ködmön C, Katalinić-Janković V, et al. Inventory study of non-tuberculous mycobacteria in the European Union. *BMC Infect Dis* 2014; 14:62.
7. Bachiyska E, Atanasova Y, Yordanova S, et al. Five-year study of non-tuberculous mycobacteria isolates in Bulgaria. 35th Congress ESM, Vienna. 2014 P 132. 2014; p. 88.
8. Bhatti MA, Turner DPJ, Chamberlain ST. *Mycobacterium marinum* hand infection: cases reports and review of literature. *Br J Plast Surg* 2000; 53(2):162–5.
9. Lahey T. Invasive *Mycobacterium marinum* infections. *Emerg Infect Dis* 2003; 9(11): 1496–8.
10. Yanqing Chen, Haiqin Jiang, Wenyue Zhang, et al. Diagnostic value of T-SPOT.TB test in cutaneous mycobacterial infections. *Acta Derm Venereol* 2018; 98: 989–90.
11. Rallis E, Koumantaki-Mathioudaki E. Treatment of *Mycobacterium marinum* cutaneous infections. *Expert Opinion on Pharmacotherapy* 2007; 8(17): 2965–78.
12. Aubry A, Chosidow O, Caumes E, et al. Sixty-three cases of *Mycobacterium marinum* infection: clinical features, treatment, and antibiotic susceptibility of causative isolates. *Arch Intern Med* 2002; 162: 1746–52.

# Первые этиологически подтверждённые случаи инфекции *Mycobacterium Marinum* в Болгарии

Елизабета Бачийска, Юлиана Атанасова, Ана Байкова, Станислава Йорданова, Яна Тодорова

Национальная референс-лаборатория по туберкулёзу, София, Болгария, Национальный центр инфекционных и паразитарных болезней, София, Болгария

**Автор для корреспонденции:** Елизабета Бачийска, Национальная референс-лаборатория по туберкулёзу, бул. „Столетов“ № 44А, 1233 София, Болгария; E-mail: elizabetbatchiiska@abv.bg; тел.: +359 2 944 64 45

---

**Дата получения:** 10 октября 2019 ♦ **Дата приемки:** 19 декабря 2019 ♦ **Дата публикации:** 30 июня 2020

---

**Образец цитирования:** Bachiyska E, Atanasova Y, Baykova A, Yordanova S, Todorova Y. First etiologically confirmed cases of *Mycobacterium marinum* infection in Bulgaria. *Folia Med (Plovdiv)* 2020;62(2):398-402. doi: 10.3897/folmed.62.e47220.

---

## Резюме

Целью данного исследования было описание двух микробиологически подтверждённых случаев *Mycobacterium marinum* инфекции кожи и мягких тканей в Болгарии. Изоляция штаммов нетуберкулёзных микобактерий (НТМ) и идентификацию их видов была проведена в НРЛ ТБ, НЦИПБ в специальных средах и условиях культивирования и ПЦР на основе метода линейной гибридизации (LPA) из положительных культур. У обоих пациентов были профессии, тесно связанные с рыбой и водоёмами, и у обоих были сходные клинические проявления инфекции *M. marinum*, известной как “swimming pool” (плавательный бассейн) или “fish tank” (ёмкость для разведения рыбы) гранулома. Длительное специфическое лечение комбинацией по меньшей мере из двух препаратов – рифампицин плюс этамбутол и некоторые осложнения оказались серьёзной проблемой как для врачей-клиницистов, так и для пациентов.

---

## Ключевые слова

LPA, микобактериоз, инфекция *Mycobacterium marinum*, НТМ

---