



# A Unique Complication after a Routine Operation – Late Pseudoaneurysm of the Brachial Artery after Plate Fixation of Humeral Shaft Fracture. A Case Report and Review of the Literature

Boris Kyurkchiev<sup>1</sup>, Borislav Zlatev<sup>1</sup>, Todor Georgiev<sup>2</sup>, Dian Enchev<sup>2</sup>

<sup>1</sup> Department of Orthopedic Surgery, Military Medical Academy, Sofia, Bulgaria

<sup>2</sup> Fourth Orthopedic and Trauma Clinic, NI Pirogov University Hospital, Sofia, Bulgaria

**Corresponding author:** Borislav Zlatev, Department of Orthopedic Surgery, Military Medical Academy, 3 Georgi Sofiiski St., 1606, Sofia, Bulgaria;  
E-mail: bobizlatev@yahoo.com; Tel.: +359 895 035 555

**Received:** 10 Dec 2019 ♦ **Accepted:** 14 Feb 2020 ♦ **Published:** 30 Sep 2020

**Citation:** Kyurkchiev B, Zlatev B, Georgiev T, Enchev D. A unique complication after a routine operation – late pseudoaneurysm of the brachial artery after plate fixation of humeral shaft fracture. A case report and review of the literature. Folia Med (Plovdiv) 2020;62(3):610-4. doi: 10.3897/folmed.62.e49215.

## Abstract

We report an extremely rare case of an 82-year-old woman with pseudoaneurysm of the brachial artery developed 22 months after a plate osteosynthesis with angularly stable locking plates for the proximal humerus. The condition was initially misdiagnosed as a tumor by the attending physician, and the patient was referred to an oncological unit. The case was successfully managed by a multidisciplinary team consisting of orthopedic and vascular surgeons.

An up-to-date review of the available literature is also provided. The pseudo-aneurysms of the axillary and the distal peripheral arteries of the upper limb are a rare but potentially dangerous complication because the thromboembolism could lead to gangrene and amputation of the extremity. Despite casuistic, they should be taken into consideration in the differential diagnosis after plate osteosynthesis. Proper operative technique and constant vigilance when orthopedic implants are used are of paramount importance, which is actually the emphasis of this report.

## Keywords

humeral shaft fracture, multidisciplinary approach, plate osteosynthesis, pseudoaneurysm of the brachial artery

## INTRODUCTION

Nowadays, plate fixation is a routine operation and gold standard for the treatment of humeral shaft fractures with a complication rate of 7.8%.<sup>1</sup> The most frequent complications are infection, radial nerve injury, and nonunion. Some extremely rare complications, however, may challenge even the experienced orthopedic surgeons. Herein we present a

unique case of pseudoaneurysm of the brachial artery developed almost 2 years after plate fixation.

An aneurysm is a localized, blood-filled balloon-like bulge in the wall of a blood vessel, with no less than 50% increase of its normal diameter.<sup>2</sup> In contrast to the true aneurysms, the false (or pseudoaneurysm) has no own wall and is confined by the surrounding tissues. Usually, they are a late complication after trauma percutaneous arterial

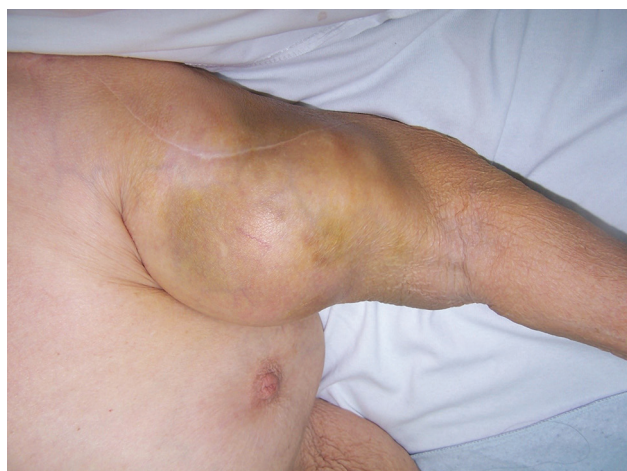procedures such as arteriography, arterial grafting, or when the artery is used for injection, usually by drug abusers.<sup>3,4</sup>

The aim of the present work was to emphasize the importance of technical details and raise the awareness that routine operations may lead to “not routine” complications.

## CASE REPORT

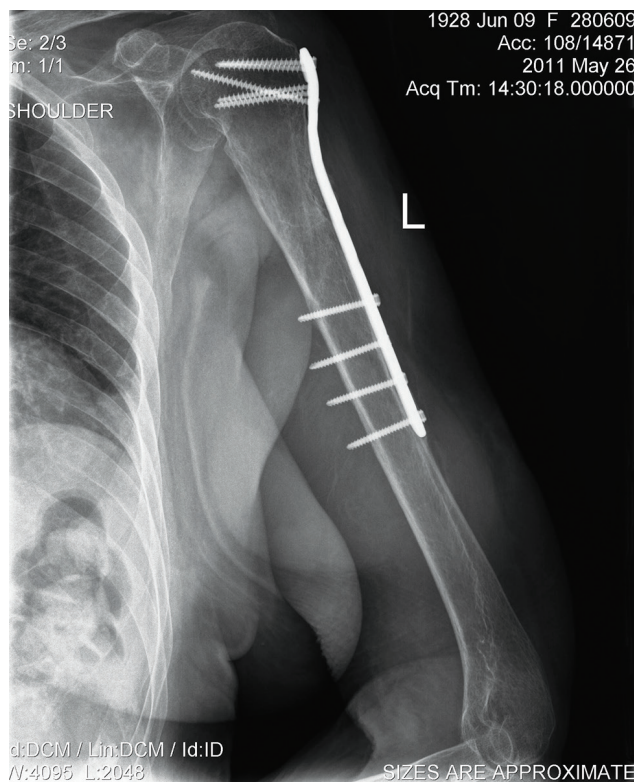
An 82-year-old woman was admitted to the Department of Orthopedic Surgery complaining of severe pain in the left arm, incapacity of active motions in the left shoulder, and appearance of swelling and subcutaneous hematoma in the same region. The clinical examination revealed livid subcutaneous hematoma, extended to the elbow, impossible active, and very painful passive range of motion of the shoulder. The antero-posterior and lateral X-ray of the left shoulder demonstrated a proximal humeral fracture, type 11-B2.3, according to AO/ASIF classification<sup>5,6</sup> or three fragmental fracture of the proximal humerus with dislocation of the shaft and non-dislocated fracture of greater tubercle according to Neer classification.<sup>7-9</sup> A standard operative protocol was used: general anesthesia, “beach-chair” position, and X-ray control. The fracture side was accessed through the deltoid-pectoral approach. Intra-operatively, an anatomical reduction and internal fixation with an angularly stable locking plate (eight holes) were performed. The patient had an uneventful recovery and was discharged on day 5 postoperatively.

Twenty-two months after the initial accident, the patient was readmitted due to a new trauma at the same place. The staff in the nursing house noticed the appearance of a bulk increasing progressively from the medial aspect of the left arm. She was diagnosed with “tumor formation in the region of left arm” and referred to the National Oncological Hospital from where she was transferred to the attending orthopedic surgeon. The examination revealed painless, pulsating tumor formation in the anterior aspect of the left arm, in the middle of the operative scar, 12-14 cm in length and about 10 cm in diameter, accompanied by limited mobility of the arm (**Fig. 1**).



**Figure 1.** Antero-posterior X-ray view of left humerus, after the second intervention.

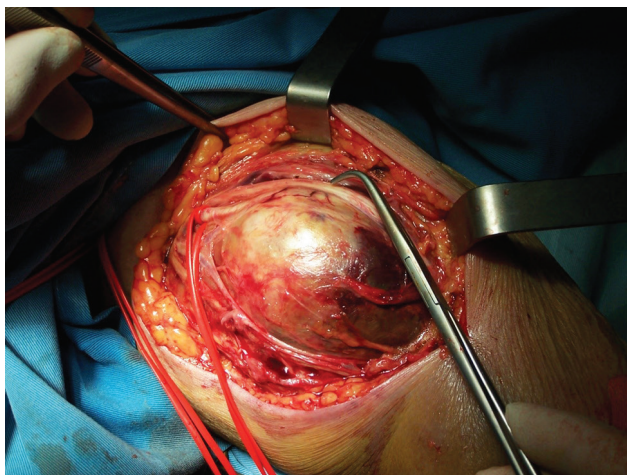
The overlying skin was stretched with suffusions. There were no enlarged lymphatic nodules in the armpit and cubital fossa. A weak to absent pulsation of the radial artery, but preserved capillary phenomenon and hot fingers were noted. No neurological disturbance was found. She had a full range of painless, active, and passive motions in joints of the left upper limb. The X-ray examination showed a complete consolidation of the fracture without signs of osteolysis and a change in the position of implants as well (**Fig. 2**).



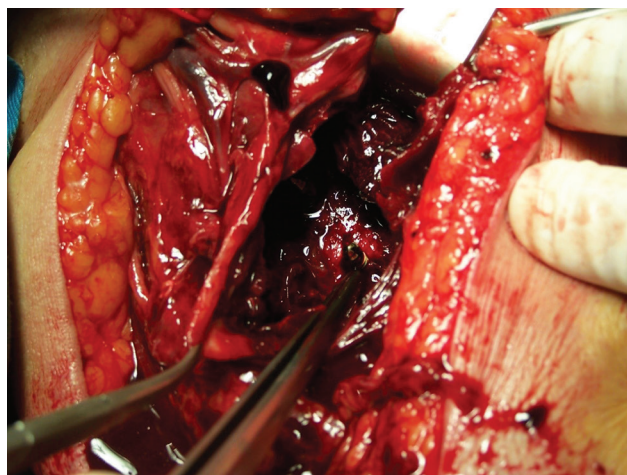
**Figure 2.** External view of injured left upper limb (the suffusions in the formation area and the deltoid-pectoral approach scar are visible).

The color arterial Doppler ultrasonography revealed pseudo-aneurysm of the left brachial artery. She underwent an operation by a multidisciplinary team on the next day. Through incision in the medial surface of left brachium, a large, strenuous, and pulsating tumor formation was found, about 12 cm in length and about 8-10 cm in diameter. The brachial artery and median nerve were found over the formation and were dislocated gently (**Fig. 3**). After proximal and distal clamping, the formation was opened, which turned out to be a false aneurysm filled with an abundance of fresh and old clots. A defect 5 cm long and 2 cm wide was found lying on the lateral wall of the brachial artery. After removal of the clots, in-depth, the prominent tips of the four distal locking screws were found on the medial surface of the humerus (**Fig. 4**). There was free communication with the lumen of the aneurysmal sack (**Fig. 5**). The screw was cut close to the bone surface. The defect of the arterial wall was restored through an auto-venous patch from the left basili-

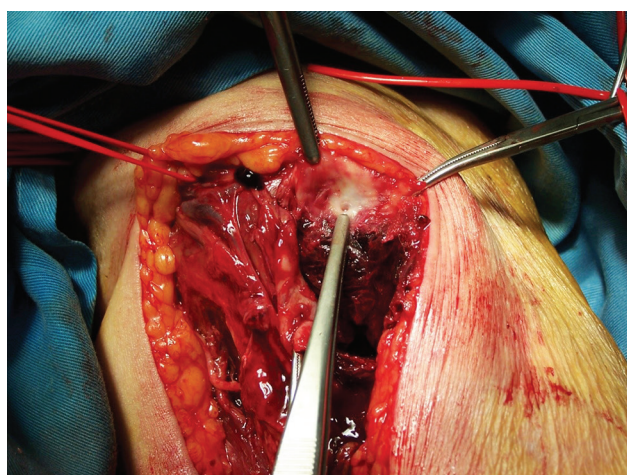




**Figure 3.** Brachial artery and median nerve dislocated laterally and above the formation.



**Figure 4.** The locking screw, which caused the perforation of the left brachial artery (the tip of the tweezers).



**Figure 5.** The tip of the tweezers points to the perforation in the left brachial artery wall.

ca vein. The sack of aneurysm was plicated on the humerus. The patient had an uneventful recovery and was discharged 4 days postoperatively.

## DISCUSSION

Aneurysms can develop in all arteries of the human body.<sup>10</sup> Aneurysms at less common locations are generally due to major trauma, syphilis, Marfan syndrome, or infection. Atherosclerotic aneurysms are often seen in large arteries and in patients of advanced age. In contrast, the pseudo-aneurysms after penetrating or blunt trauma are seen in patients of every age and at any location.<sup>11</sup> Post-traumatic pseudo-aneurysm development is very rare in the peripheral arteries and is generally a late consequence of trauma.<sup>12</sup> The frequency of peripheral arterial aneurysms in the upper extremities is much less than in the lower extremities.<sup>13</sup> Peripheral arterial pseudo-aneurysms with distal locations, particularly in the brachial artery, cause thromboembolic complications in the hand and fingers. Their diagnosis and surgical treatment are very important because they can cause severe disabilities, including a loss of upper extremity or fingers.<sup>14</sup> Common sites for aneurysm formation in the upper extremity are the subclavian artery and the hand. However, a false aneurysm due to a trauma can occur throughout the entire arterial system of the upper limb. Those due to penetrating trauma or needle puncture are the most common forms of aneurysm of the hand.

Very few studies devoted to this topic were found in the literature – two publications after closed reduction of humeral fracture<sup>15</sup>, one after blunt trauma in the humerus region<sup>16</sup>, and two after supracondylar fractures in children<sup>17</sup>. The majority of iatrogenic post-traumatic pseudo-aneurysms of the vessels of the upper extremity are localized in the humeral head region, the armpit, and the palm. Most of them are caused by the use of Kirschner's wires and screws for intramedullary nails. To the best of our knowledge, there is no reported case in which the cause for the perforation of the artery is the locking screw of an angularly stable locking plate. In fact, this complication is a result of non-adherence to the rules and operative technique of using these implants. Actually, to avoid the use of excessively long screws and their proper placement in the locking hole of the plate, specific sleeves and drills with scales in centimetres are used in practice. In some cases, if the scales are not clearly visible, the measurement could be misleading. In particular areas, the usage of longer screws is not a problem, but in the brachium, the neuro-vascular anatomy predisposes to serious complications, as in our case.

The fractures in the proximal humerus are among the most frequent traumas, and many implants have been developed for their treatment. In a study during which various proximal humeral nails are implanted in the humerus of the cadavers, Nijs et al. demonstrated a significantly increased risk of damage of the axillary nerve and the ascending branch of the anterior circumflex artery after insertion

of proximal screws, even under X-ray control.<sup>18</sup>

Most incidental post-traumatic pseudo-aneurysms are the outcome of daily or war-time penetrating injuries caused by gunshots or blank weapons or are found in intravenous drug abusers and after industrial traumas.<sup>19</sup> A minor blunt trauma may cause pseudo-aneurysms in patients who are prone to hemorrhage.<sup>20</sup> In some cases, the patients with pseudo-aneurysms are admitted to hospital months or years after the trauma.<sup>17,19,21,22</sup> The first symptom of the aneurysms of the upper limb could be neural damage or compression of an adjacent nerve.<sup>23</sup> In contrast, in our case, the only complication was the growing lump. Delayed treatment could lead to hemorrhage, venous swelling of the limb, skin erosions, and mostly, compression of the adjacent neural structure due to the increase of the pseudo-aneurysm.<sup>24,25</sup> In the modern era, many aneurysms can be managed by means of an endovascular approach. The presented case, however, was managed ten years ago, and at that time, the covered stents were not introduced in practice. Moreover, no endovascular techniques were available at our institution. Last but not least, in similar cases, the endovascular approach can be dangerous because the sharp tip of the screw may cause a new rupture.

## CONCLUSION

The angularly stable locking plates (PHLP) are frequently used for the treatment of B and C type of proximal humeral fractures (even through MIPO technique). Due to the proximity of the neurovascular structures, there is a potential risk of iatrogenic injury. The locking screws could endanger the axillary nerve and the ascending branch of the anterior circumflex humeral artery (an important blood supply of the humeral head), as well as the brachial artery and the median nerve along the humeral shaft as in the case reported herein. This warrants constant vigilance during the operative intervention. Last but not least, X-ray control should be used following each major step of the operational procedure because the exaggerated self-confidence of the surgeon could sometimes lead to the abovementioned negative results.

Despite the low rate in the daily clinical practice, due to the increase in life expectancy, these types of pseudo-aneurysms will probably become more frequent. Therefore, they should be taken into consideration in the differential diagnosis following the use of various implants for osteosynthesis.

## Acknowledgements

The authors thank Cvetko Petrov for the technical support.

## REFERENCES

1. Gottschalk MB, Carpenter W, Hiza E, et al. Humeral shaft fracture fixation: incidence rates and complications as reported by American Board of Orthopaedic Surgery Part II Candidates. *J Bone Joint Surg Am* 2016;

- 98(17): e71.
2. Dorland W. *Dorland's Illustrated Medical Dictionary*. 32nd edition, W.B. Saunders Company, 2011.
3. Kumar V, Abbas AK, Fausto N, editors. *Robbins & Cotran Pathologic Basis of Disease*. 7th edition, W.B. Saunders Company, 2004.
4. Haimovici H, Ascher E, Hollier L, et al., editors. *Haimovici's Vascular Surgery*. 5th edition, Blackwell Publishing; 2004; 967–70.
5. Müller M, Allgöwer M, Schneider R, et al. *Manual of internal fixation*, 3rd edition. Springer Verlag, 1991.
6. Müller ME. CCF – Comprehensive Classification of Fractures I & II, M. E. Müller Foundation, 1996.
7. Neer C. Displaced proximal humeral fractures I: classification and evaluation. *J Bone Joint Surg* 1970; 52: 1077.
8. Canale S, Beaty J. *Campbell's Operative Orthopaedics*. 11th edition, Mosby Elsevier, 2007.
9. Mostofi S. *Fracture classifications in clinical practice*. London: Springer-Verlag London; 2006.
10. Crawford ES, De Bakey ME, Cooley DA. Surgical considerations of peripheral arterial aneurysms. *Arch Surgery* 1959; 78: 226–38.
11. Yilmaz A, Arslan M, Demirkilic U, et al. Missed arterial injuries in military patients. *Am J Surg* 1997; 173(2): 110–14.
12. Napolitano A, Napolitano L, Francomano F, et al. Aneurysms of the subclavian artery: clinical experience. *Ann Ital Chir* 1998; 69: 311–6.
13. Wielenberg A, Borge M, Demos T, et al. Traumatic pseudoaneurysm of the brachial artery. *Orthopedics* 2000; 23(12): 1250,1322–4.
14. Nugud O, Hedges A. Axillary artery pseudoaneurysm. *Int J Clin Pract* 2001; 55: 494–9.
15. Deirdre M, Graham R, Ronan R, et al. Pseudoaneurysm of the brachial artery following humeral fracture. *Vasc Endovascular Surgery* 2008; 42: 65–8.
16. Kakar B, Babar K, Khan A, et al. Surgical experience of post-traumatic pseudo aneurysm of the brachial artery at a tertiary care hospital. *J Pak Med Assoc* 2008; 58(4): 224.
17. Luria S, Sucar A, Eylon S, et al. Vascular complications of supracondylar humeral fractures in children. *J Pediatr Orthop* 2007; 16(2): 133–43.
18. Nijs S, Sermon A, Broos P. Intramedullary fixation of proximal humerus fractures: do locking bolts endanger the axillary nerve or the ascending branch of the anterior circumflex artery? A cadaveric study. *Patient Safety in Surgery* 2008; 2: 33.
19. Johnston K, Rutherford R, Tilson M, et al. Suggested standards for reporting on arterial aneurysms. Subcommittee on Reporting Standards for Arterial Aneurysms, Ad Hoc Committee on Reporting Standards, Society for Vascular Surgery and North American Chapter, International Society for Cardiovascular Surgery. *J Vasc Surg* 1991; 13: 452–8.
20. Kumar S, Agnihotri S, Khanna SK. Brachial artery pseudoaneurysm following blood donation. *Transfusion* 1995; 35(9): 791.
21. Haimovici H. Peripheral arterial aneurysms. In: Haimovici H, Ascher E, Hollier LH, Strandness D, Towne J, editors. *Haimovici's vascular surgery*. Cambridge (MA): Blackwell Science; 1996. p. 893–909.
22. Tetik O, Yetkin U, Yilik L, et al. Right axillary pseudoaneurysm causing permanent neurological damage at right upper limb: A case report. *Turk J Vasc Surg* 2002; 2: 102–4.
23. Ergungor M, Kars H, Yalin R. Median neuralgia caused by brachial pseudoaneurysm. *Neurosurgery* 1989;24(6):924–5.
24. Robbs J, Naidoo K. Nerve compression injuries due to traumatic false aneurysm. *Ann Surg* 1984;200(1):80–2.
25. Court-Brown C, Caesar B. Epidemiology of adult fractures: A review. *Injury* 2006;37:691–7.

# Крайне редкое осложнение после рутинной операции – поздний псевдоаневризм плечевой артерии после фиксации диафизарного перелома пластиной. Клинический случай и обзор литературы

Борис Кюркчиев<sup>1</sup>, Борислав Златев<sup>1</sup>, Тодор Георгиев<sup>2</sup>, Диан Енчев<sup>2</sup>

<sup>1</sup> Клиника ортопедии и травматологии, Военно-медицинская академия, София, Болгария

<sup>2</sup> Четвёртая клиника ортопедии и травматологии, УМБАЛСМ „Н. И. Пирогов“, София, Болгария

**Адрес для корреспонденции:** Борислав Златев, Клиника ортопедии и травматологии, Военно-медицинская академия, ул. „Георги Софийски“ №3 София, Болгария; E-mail: bobizlatev@yahoo.com; Тел.: +359 895 035 555

---

**Дата получения:** 10 декабря 2019 ♦ **Дата приемки:** 14 февраля 2020 ♦ **Дата публикации:** 30 сентября 2020

---

**Образец цитирования:** Kyurkchiev B, Zlatev B, Georgiev T, Enchev D. A unique complication after a routine operation – late pseudoaneurysm of the brachial artery after plate fixation of humeral shaft fracture. A case report and review of the literature. Folia Med (Plovdiv) 2020;62(3):610-4. doi: 10.3897/folmed.62.e49215.

---

## Резюме

Мы сообщаем о крайне редком случае 82-летней женщины с псевдоаневризмой плечевой артерии, развившейся через 22 месяца после остеосинтеза с угловыми стабильными фиксирующими пластинами для проксимального отдела плечевой кости. Первоначально врач диагностировал её состояние как опухоль, и пациентка была направлена в онкологическое отделение. Лечение было успешно проведено с участием мультидисциплинарной команды, состоящей из хирургов-ортопедов и сосудистых хирургов. Актуальный обзор литературы также включен. Псевдоаневризмы подмышечных и дистальных периферических артерий верхней конечности являются редкими, но потенциально опасными осложнениями, так как тромбоэмболия может привести к гангрене и ампутации конечности. Хотя они и казуистические, их следует учитывать при дифференциальной диагностике после остеосинтеза с применением пластин. Надлежащая хирургическая техника и повышенное внимание при использовании ортопедических имплантатов чрезвычайно важны, что на самом деле является идеей этого доклада.

---

## Ключевые слова

перелом диафиза, мультидисциплинарный подход, остеосинтез с применением пластин, псевдоаневризма плечевой артерии

---