

# A Collision between Cavernous-Capillary Hemangioma with Stromal Luteinization and Serous Cystadenoma

Spasimir T. Shopov<sup>1,2</sup>

<sup>1</sup> Department of Pathology, Hospital "Parvomai" Ltd, Parvomai, Bulgaria

<sup>2</sup> Department of General and Clinical Pathology, Medical University of Plovdiv, Plovdiv, Bulgaria

**Corresponding author:** Spasimir Todorov Shopov, Department of Pathology, Hospital "Parvomai" Ltd, 51 Knyaz Boris I St., Parvomai, Bulgaria; E-mail: sshopov1@abv.bg; Tel.: +359 32 699 916

**Received:** 27 Feb 2020 ♦ **Accepted:** 9 Apr 2020 ♦ **Published:** 31 Dec 2020

**Citation:** Shopov ST. A collision between cavernous-capillary hemangioma with stromal luteinization and serous cystadenoma. Folia Med (Plovdiv) 2020;62(4):851-5. doi: 10.3897/folmed.62.e51551.

## Abstract

A collision tumor represents a coexistence of two adjacent but histologically distinct tumors without histologic admixture in an organ. Serous tumors of the ovary are the most common forms of epithelial tumors, and cavernous hemangiomas are rare in the ovary. However, a collision between them is an extremely rare pathology. Here the author presents a report of a 74-year-old woman whose ultrasound examines establishes rounded left ovary formation with hypo- and hyperdense sections. Paraclinical: CA125 within normal range. Serum levels free testosterone 3.79 nmol/l (normal 0.49-2.64 nmol/l for women). The histology showed benign serous cystadenoma and vascular lesions composed of capillary and cavernous vessels amongst luteinized stromal cells. The luteinized cells were positive for inhibin A. The endothelial cells were negative for estrogen and progesterone receptor. A search was conducted in the Medline database via PubMed using the terms: 'hemangioma', 'ovary', 'collision', 'serous cystadenoma', no more than 70 articles for ovarian hemangiomas appeared, and no articles for a collision between serous cystadenoma and mixed hemangioma with stromal luteinization in the ovary. From the reference, this is the first reported case of collision between serous cystadenoma and mixed cavernous-capillary hemangioma with stromal luteinization in the ovary. This rare case of collision between tumors in the ovary sheds light on possible tumor pathology in the woman's reproductive system, which must be considered by gynaecologists and pathologists.

## Keywords

collision tumor, hemangioma, ovary, serous cystadenoma

## INTRODUCTION

Collision tumors are rare neoplasms characterized by histologically different tumors developing in close proximity in an organ from two divergent lineages.<sup>1</sup> Tumors with serous differentiation represent 46% of all surface epithelial-stromal ovarian neoplasms of which 50% are benign serous tumors. These are usually cystic.<sup>2</sup> Hemangiomas are benign vascular tumors. Those arising in the ovary are very rare. The documented cases of ovarian hemangioma are around 60.<sup>3</sup> Usually, the ovarian hemangioma is an ac-

cidental finding at surgery or autopsy. In some patients, there is abdominal pain due to torsion, enlargement of the abdomen due to mass effect or ascites.<sup>3,4</sup> Lesions are usually unilateral, rarely bilateral.<sup>4</sup> Several ovarian hemangiomas with stromal luteinization with or without hyperandrogenism have been reported.<sup>4</sup> The present study reports an extremely rare collision between mixed cavernous-capillary hemangioma with stromal luteinization and serous cystadenoma without hyperandrogenism, describing the clinicopathologic features and differential diagnosis of ovarian hemangioma.

## CASE REPORT

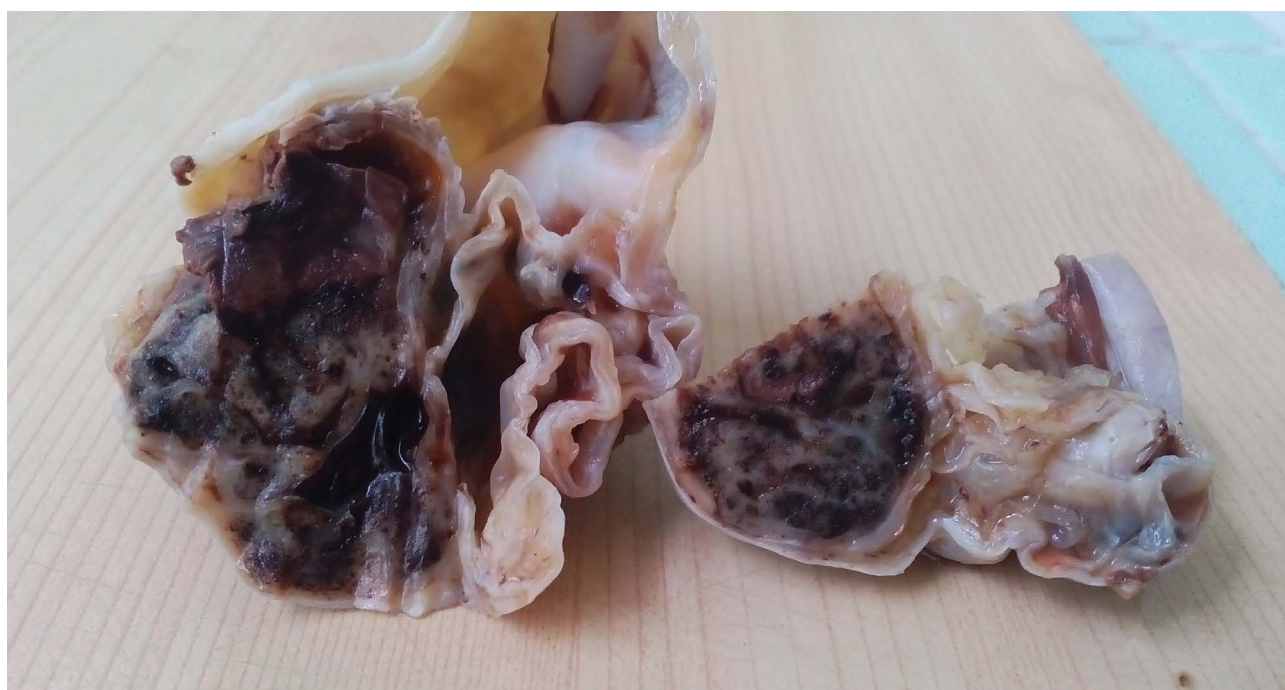A 74-year-old woman was admitted to the gynecological ward with a history of lower abdominal pain that had intensified over the last few days. The patient denied weight changes, fever, vomiting, vaginal discharge, and hormone replacement therapy. A pelvic exam demonstrated a mild vaginal prolapse. Complete blood counts and serum chemistries were within normal limits, except the serum levels of free testosterone (3.79 nmol/l – the normal range for women being 0.49–2.64 nmol/l). Serum CA-125 level was within normal range (19.40 U/ml). A transvaginal ultrasound examination demonstrated a polycystic left pelvic mass measuring 11.5 cm with a hyper-echoic sector. The patient underwent laparotomy with a total hysterectomy, salpingo-oophorectomy with part of the omentum. The postoperative course was uneventful. Macroscopically, the outer surface of the uterus, right ovary, and part of omentum was unchanged. The left ovary had a 12-cm cyst, smooth and whitish. On sectioning, the severed surface of the ovary was cystically filled with clear fluid. A brownish area with a spongy texture was noticeable in the periphery of the cyst (5/4/3.5 cm) (**Fig. 1**). The histopathology study revealed benign sections in the cystic part, a thin fibro-collagenous cyst wall lined with flattened epithelium (**Fig. 2a**) and part of the ovary (**Fig. 2b**), vascular lesions composed of numerous cavernous and capillary vessels with a rim of surrounding luteinized ovarian stromal cells (**Fig. 2c, 2d**). Parts of the vessels were thrombosed (**Fig. 2e**). This finding was present in the spongy texture of the left ovary. The endothelial lining cells showed no nuclear atypia or mitoses. The luteinized stromal cells had abundant granular cytoplasm, and some had a clear vacuolated cytoplasm (**Fig. 2d**). No teratoma or epithelial tumors were found. The endothelial

cells were negative for estrogen receptor (ER) and positive for CD34. The luteinized stromal cells were negative for HMB45, and Ki67 was positive in single cells. The luteinized stromal cells were strongly positive for Inhibin A and had no PAS-D resistant cytoplasmic crystals. Presence of hemosiderin pigment that was also positive for HMB45. The cystic part was made up of a fibrous wall with sparsely preserved flattened cells. The two tumors were histologically adjacent but did not mix. In one area, single endometrial glands were encountered (**Fig. 2f**).

**Diagnosis:** A collision mixed cavernous-capillary hemangioma with stromal luteinization and serous cystadenoma of the left ovary. Endometriosis ovary. Adenomyosis.

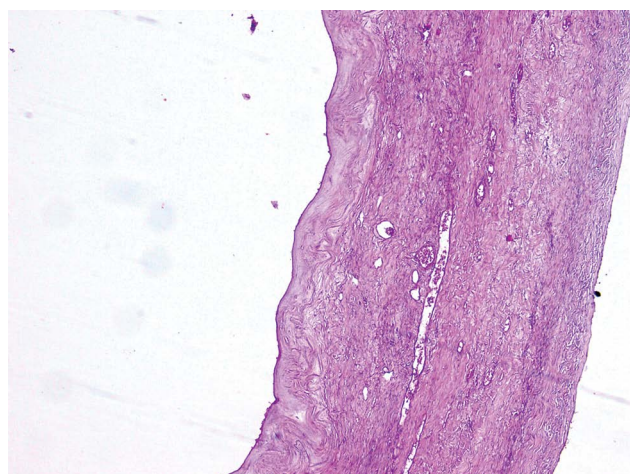
## DISCUSSION

Despite the many reports of collision tumors, their appearance with the ovaries is rare, especially in the collision of two benign variants.<sup>1</sup> Surface epithelial-stromal tumors are the commonest types of ovarian tumors. Ovarian hemangiomas, especially the mixed capillary-cavernous type with luteinized stroma, are extremely rare.<sup>1,4</sup> A combination of these tumors is extremely rare. The pathogenesis of collision tumors has remained controversial. These tumors are considered multiple synchronous tumors in a single organ because these components are separated from each other by a stroma without histological admixture. Various combinations have been reported. Various pathogenetic links are suggested for the development of collision tumors: accidental occurrence; a simultaneous proliferation of two different cell lines; dividing the pluripotent stem cell into two; carcinogenic agent; an oncogenic growth factor produced

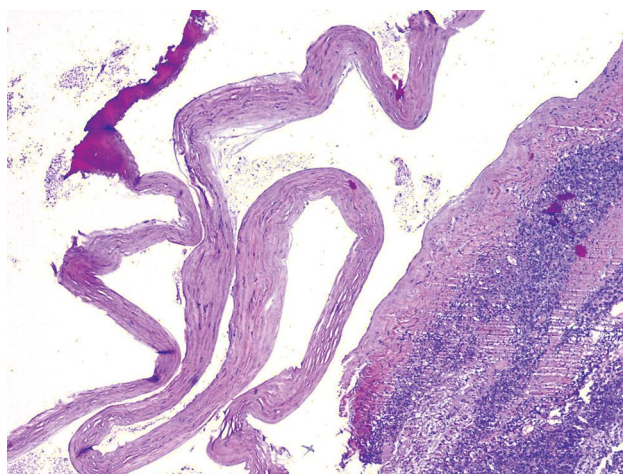


**Figure 1.** Macroscopic picture: serous cystadenoma and ovary hemangioma. Cut surface.

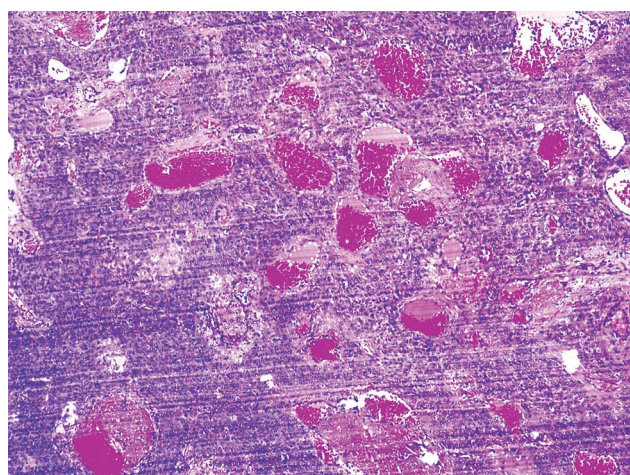




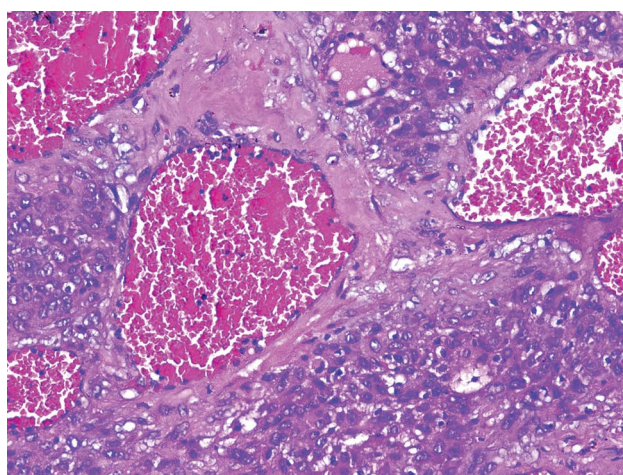
2a



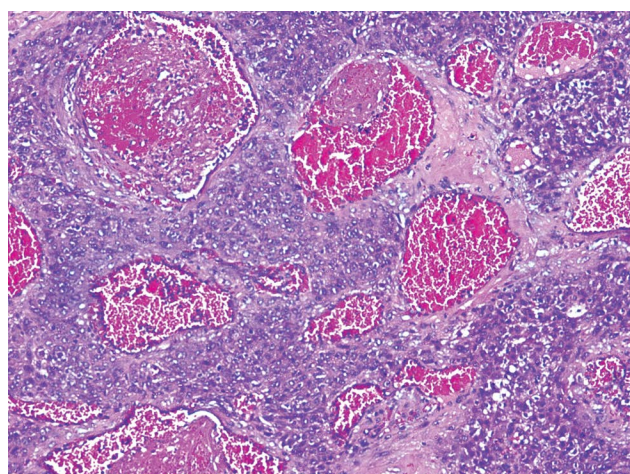
2b



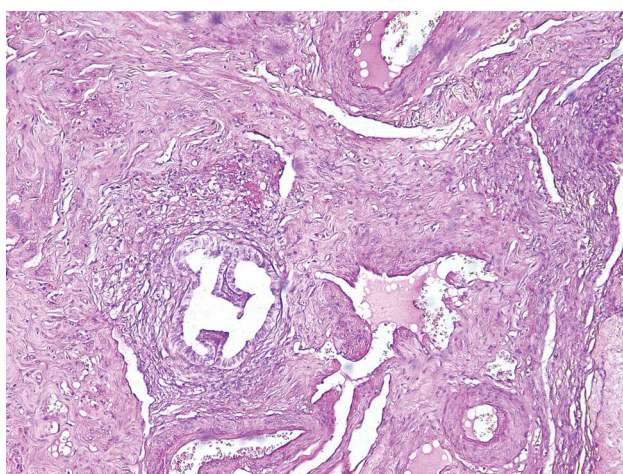
2c



2d



2e



2f

**Figure 2.** Histology (hematoxylin and eosin): **a.** A wall of serous cystadenoma with fibrosis (enlargement  $\times 100$ ); **b.** A wall of serous cystadenoma lined with flattened epithelium and part of the ovary (enlargement  $\times 50$ ); **c, d.** vascular lesions composed of numerous cavernous and capillary vessels with a rim of surrounding luteinized ovarian stromal cells (enlargement  $\times 50$ ;  $\times 200$ ); **e.** Parts of the vessels are thrombosed (enlargement  $\times 100$ ); **f.** single endometrial glands (enlargement  $\times 100$ ).



by a metastatic tumor; alteration in the microenvironment.<sup>1</sup> The etiology of ovarian hemangioma is controversial. Various mechanisms for its occurrence are assumed.<sup>4</sup> The origin of serous cystadenoma is explained by metaplasia of the ovarian surface epithelium.<sup>2</sup> Various variants of ovarian collision tumors have been reported<sup>1,2</sup> but the case of collision between mixed cavernous-capillary hemangioma with stromal luteinization and serous cystadenoma of the ovary is the first of its kind. Although benign serous tumors are typically lined with an epithelium similar to that of the fallopian tube with ciliated and less frequently nonciliated secretory cells, cysts with flattened lining may be seen, which represent desquamation of the lining epithelium<sup>2</sup>, as is the presented case. Even though the ovary is very rich in vessels, ovary hemangiomas are very rare, with only around 60 reported cases.<sup>3</sup> Ovarian hemangiomas can occur at any age. Most are of the cavernous type, and rarely they are of the mixed cavernous-capillary or pure capillary type.<sup>5</sup> Usually, they are incidental findings, but some may mimic ovarian carcinoma presenting with an adnexal mass, elevated CA-125, and ascites.<sup>6</sup> Some authors believe that hyperestrogenism resulting from stromal luteinization is the inciting event in the development of ovary hemangioma.<sup>5</sup> Miliars et al. found that endothelial cells were positive for ER and PR<sup>5</sup> – in our case, though, the endothelial cells were negative for ER and PR. Ovarian hemangiomas may have stromal luteinization and various hypotheses have been proposed for its formation.<sup>7</sup> Like other cases, our case showed a layer of stromal luteinization surrounding the mixed cavernous-capillary hemangioma. Ovarian hemangiomas initiate stromal luteinization and can lead to hyperandrogenism and hyperestrogenism.<sup>8</sup> The luteinized stromal cells produce androgens that can be converted to estrogen in the adipose tissue. This can result in both hyperandrogenism and hyperestrogenism. In our patient, the serum levels of free testosterone was 3.79 nmol/l (normal 0.49–2.64 nmol/l for women). Only a few cases of ovarian hemangiomas have had hyperandrogenism.<sup>8</sup> In the reported case, there were no signs of virilization, but there were also reported cases of virilization.<sup>8</sup> To our knowledge, this is the first reported case of collision between mixed cavernous-capillary hemangioma with stromal luteinization and serous cystadenoma of the left ovary with increased testosterone with no signs of virilization. While the relationship

between ovarian hemangiomas and stromal luteinization remains unclear, our case provides some evidence to support the hypothesis that mechanical force may be the inciting event in the development of stromal luteinization. This collision can mimic carcinoma when serum CA-125 is significantly high.

## CONCLUSIONS

This is the first case of a collision between mixed cavernous-capillary hemangioma with stromal luteinization and serous cystadenoma of an ovarian. The absence of estrogen and progesterone receptors in the endothelial cells of the hemangioma suggests that ovarian hemangiomas may occur independently of stimulation by estrogen and progesterone.

## REFERENCES

1. Shopov ST. A collision tumor of the ovary during pregnancy - rare combination. *J Med-Clin Res & Rev* 2019; 3(6):1–3.
2. Jayalakshmy PS, Poothiade U, Krishna G, et al. Ovarian fibroma with serous cystadenoma - an unusual combination: a case report. *Case Rep Obstet Gynecol* 2012; 2012:641085.
3. Ziari K, Alizadeh K. Ovarian hemangioma: a rare case report and review of the literature. *Iran J Pathol* 2016; 11(1):61–5.
4. Huang RS, Covinsky M, Zhang S. Bilateral ovarian capillary hemangioma with stromal luteinization and hyperandrogenism. *Ann Clin Lab Sci* 2013; 43(4):457–9.
5. Miliaras D, Papaemmanouil S, Blatzas G. Ovarian capillary hemangioma and stromal luteinization: a case study with hormonal receptor evaluation. *Eur J Gynaecol Oncol* 2001; 22(5):369–77.
6. Erdemoglu E, Kamaci M, Ozen S, et al. Ovarian hemangioma with elevated CA125 and ascites mimicking ovarian cancer. *Eur J Gynaecol Oncol* 2006; 27:195–6.
7. Yamawaki T, Hirai Y, Takeshima N, et al. Ovarian hemangioma associated with concomitant stromal luteinization and ascites. *Gynecol Oncol* 1996; 61:438–41.
8. Gücer F, Ozyilmaz F, Balkanlı-Kaplan P, et al. Ovarian hemangioma presenting with hyperandrogenism and endometrial cancer: a case report. *Gynecol Oncol* 2004; 94:821–4.

# Коллизия кавернозно-капиллярной гемангиомы со стромальной лютеинизацией и серозной цистаденомой

Спасимир Т. Шопов<sup>1,2</sup>

<sup>1</sup> Отделение патологии, МБАЛ „Парвомай“ – ЕООО, Парвомай, Болгария

<sup>2</sup> Кафедра общей и клинической патологии, Медицинский университет – Пловдив, Пловдив, Болгария

**Адрес для корреспонденции:** Спасимир Т. Шопов, Отделение патологии, МБАЛ „Парвомай“ – ЕООО, ул. „Княз Борис 1“ 51, Парвомай, Болгария; E-mail: sshopov1@abv.bg; Тел.: +359 32 699 916

**Дата получения:** 27 февраля 2020 ♦ **Дата приемки:** 9 апреля 2020 ♦ **Дата публикации:** 31 декабря 2020

**Образец цитирования:** Shopov ST. A collision between cavernous-capillary hemangioma with stromal luteinization and serous cystadenoma. Folia Med (Plovdiv) 2020;62(4):851-5. doi: 10.3897/folmed.62.e51551.

## Резюме

Коллизионная опухоль представляет собой сосуществование двух соседних, но гистологически различных опухолей без гистологического смешения в одном органе. Серозные опухоли яичников являются наиболее распространёнными типами эпителиальных опухолей, а кавернозные гемангиомы в яичниках встречаются редко. Однако коллизия между ними является крайне редкой патологией. Здесь автор представляет отчёт о 74-летней женщине, при ультразвуковом исследовании которой обнаружено круглое образование левого яичника с гипо- и гиперплотными участками. Параклиника: СА125 в пределах нормы. Уровни свободного тестостерона в сыворотке составляют 3.79 pmol/l (нормальное значение для женщин – 0.49-2.64 pmol/l). Гистология показала доброкачественную серозную цистаденому и сосудистые поражения, состоящие из капилляров и кавернозных сосудов между лютеинизированными стромальными клетками. Лютеинизированные клетки были положительными на ингибин А. Эндотелиальные клетки были отрицательными на рецептор эстрогена и прогестерона. В базе данных Medline с использованием PubMed было проведено исследование с использованием терминов: «гемангиома», «яичник», «коллизия», «серозная цистаденома», было опубликовано не более 70 статей о гемангиомах яичников и ни одной статьи о коллизии между серозной цистаденомой и смешанной гемангиомой с лютеинизацией стромы в яичнике.

Согласно литературным данным, это первый задокументированный случай коллизии серозной цистаденомы и смешанной кавернозно-капиллярной гемангиомы со стромальной лютеинизацией яичников. Этот редкий случай коллизии опухолей яичника проливает свет на возможную опухолевую патологию женской репродуктивной системы, которую следует учитывать гинекологам и патологам.

## Ключевые слова

коллизионная опухоль, гемангиома, яичник, серозная цистаденома