



Crohn's Disease of the Vulva: a Case Report

Kalliopi Kokkali¹, Christos Iavazzo¹, Efthimia Souka², Sofia Lekka¹, Alexandros Fotiou¹,
Eirini Geramani¹, Victoria Psomiadou¹, George Vorgias¹

¹ Department of Gynecologic Oncology, Metaxa Cancer Hospital, Piraeus, Greece

² Department of Pathology, Metaxa Cancer Hospital, Piraeus, Greece

Corresponding author: Kalliopi Kokkali, Department of Gynecologic Oncology, Metaxa Cancer Hospital, Mpotasi 51, 18537 Piraeus, Greece; E-mail: popi.koc@gmail.com; Tel.: 213 2079100

Received: 25 Aug 2020 ♦ **Accepted:** 6 Oct 2020 ♦ **Published:** 31 Dec 2021

Citation: Kokkali K, Iavazzo Ch, Souka E, Lekka S, Fotiou A, Geramani E, Psomiadou V, Vorgias G. Crohn's disease of the vulva: a case report. *Folia Med (Plovdiv)* 2021;63(6):990-3. doi: 10.3897/folmed.63.e58002.

Abstract

Crohn's disease is a multi-systemic chronic inflammatory disease that can affect various organs besides the gastrointestinal tract such as joints, uvea, and the skin. Vulvar Crohn's disease is a rare entity occurring with vulvar lesions that show typical Crohn's disease granulomatous inflammation but are not contiguous with the gastrointestinal involvement. Vulvar Crohn's disease can be easily confused with other granulomatous diseases and awareness that such involvement may precede gastrointestinal symptoms must be raised. Few cases of vulvar Crohn's disease have been reported in the literature to date. Here, we report a case of a 43-year-old woman with a 6-month history of a vulvar lesion; the patient was diagnosed with Crohn's disease of the large bowel just over a year ago.

Keywords

Crohn's disease, metastatic Crohn's disease, noncaseating granuloma, vulvar Crohn's disease

INTRODUCTION

Crohn's disease (CD) is an inflammatory bowel disorder that may affect any region of the gastrointestinal (GI) tract. Extraintestinal manifestations of the disease are also very common and they are frequently observed as inflammation of the skin, joints, and uvea.¹ Up to one-third of women with CD suffer from anogenital involvement, which may precede GI symptoms and a CD diagnosis. Vulvar CD is a rare condition, with just few cases reported in the literature.² Vulvar lesions are commonly "metastatic" in that they show typical Crohn's disease granulomatous inflammation but are not contiguous with the GI involvement.^{3,4} We report here a case of a 43-year-old woman diagnosed with Crohn's disease of the vulva manifested years after GI and other extraintestinal manifestations such as ankylosing spondylitis.

CASE REPORT

In February 2020, a 43-year-old woman presented to the Department of Gastroenterology of our institution with a 6-month history of progressively increasing painless unilateral edema and erythema in the right labia majora of the vulva. She also complained of mild abdominal pain accompanied by diarrhea and increased frequency of bowel movements. There was no fever or vaginal discharge. In December 2018, she was diagnosed with Crohn's disease of the large bowel with obstructive lesions of the descending colon and therefore she underwent left hemicolectomy. Afterwards she didn't take any medication and had no follow-up care for the disease. In her past medical history, there was ankylosing spondylitis for which she had taken different kind of medication over the years. Her family medical history was unremarkable. Colonoscopy and bi-

opsies taken revealed a CD relapse. On gynecologic examination, there was hardness, edema without tenderness in the right vulva. The clinical differential diagnosis of the vulvar lesions included metastatic Crohn's disease of the vulva, granulomatous diseases such as sarcoidosis, tuberculosis or other mycobacterial infection, sexually transmitted diseases such as lymphogranuloma venereum or granuloma inguinale, deep fungal infection, actinomycosis, chronic lymphedema, hidradenitis suppurativa. All hematological, biochemical and immunological investigations were within the normal range with the exception of a small increase in CRP to 47.1 mg/dl (normal reference value <0.5 mg/dl). Tumour markers as well as viral markers were negative. The Mantoux test was negative, too. Cultures of the rectum were positive for *C. difficile* and treatment with metronidazole was administered to the patient. The CT enterography was also compatible with bowel inflammation. A biopsy of the right labia majora was obtained. Histopathological examination revealed the presence of chronic inflammation with formation of noncaseating granuloma and abundant multinucleated giant cells (**Fig. 1**). On the basis of the clinical, laboratory and endoscopic data, and the exclusion of other granulomatous and infectious diseases, the diagnosis of metastatic Crohn's disease of the vulva was established. The patient was initially started on methylprednisolone (20 mg bid I.V.) and one infusion of infliximab was administered. She reported a progressive improvement of GI symptoms along with substantial clinical improvement of the cutaneous edema and erythema. Moreover, the inflammation markers such as CRP showed substantial decrease. The patient was discharged from the hospital with oral methylprednisolone with instructions for tapering to the maintenance dosage and another infliximab infusion in four weeks.

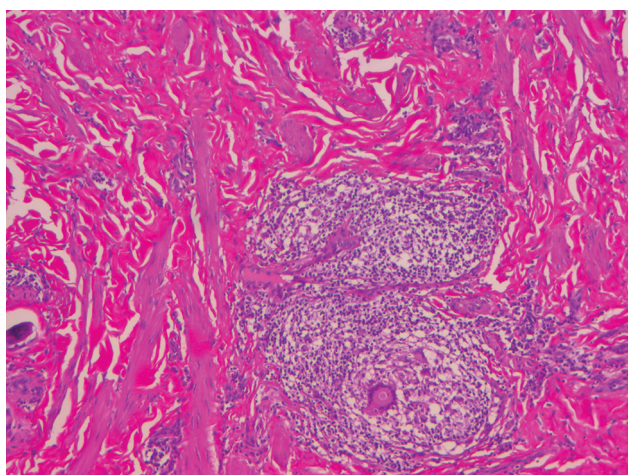


Figure 1. Histopathological examination revealed chronic inflammation with formation of noncaseating granuloma and abundant multinucleated giant cells, compatible with metastatic Crohn's disease of the vulva. (H&E, $\times 100$).

DISCUSSION

Crohn's disease of the vulva was described for the first time by Park et al.⁵ and since then few series have been reported in the literature describing vulvar lesions of CD. **Table 1** shows the characteristics of some cases reported in the recent literature (including our case) such as age, GI involvement, clinical presentation, histological findings, and different treatment modalities. The involvement of the vulva during CD can occur either by direct extension from the perineal region or by metastasis, as in our case report. Metastatic Crohn's disease of the vulva is defined as granulomatous lesions separated from the affected regions of the intestinal tract by a territory of healthy skin⁶ and it is the cause of greater than 90% of the vulvar lesions of CD⁷. Vulvar CD has been documented in females aged 8 to 74 years, with two thirds of these being in premenopausal women and 10% in children.⁴ The majority of the cases present at least 6 months after the initiation of GI symptoms. However, skin lesions may also present during, and in rare cases prior to, the onset of inflammatory bowel disease.^{4,8} In fact, no clear correlation between the presence of metastatic Crohn's disease of the vulva and the activity of the intestinal disorder or its response to treatment severity has been established.⁸ Diagnosis of vulvar Crohn's disease seems to be very challenging because of its multiple presentations. The disease is typically asymptomatic, and the diagnosis will be brought up in front of vulvar edema or hypertrophic lesions discovered by clinical examination. However, complaints such as vulvar pain or pruritus have been reported, as well as vulvar discharge or dyspareunia, and also urinary symptoms as dysuria.³ In long-standing untreated disease, patients may develop vulvar abscesses or "knife-cut" ulcers that are highly specific for extra-intestinal Crohn's disease.⁹ The disease is generally known as a great mimicker and differential diagnosis includes all infectious and noninfectious diseases with similar clinical manifestations, such as actinomycosis, sarcoidosis, tuberculosis, candida infection, herpes virus infection, schistosomiasis, lymphogranuloma venereum, chronic lymphadenitis, cellulitis, hidradenitis suppurativa, a foreign body reaction, and neoplasia.¹⁰ Although a detailed history as well as physical examination may help narrow the differential, the confirmation of the diagnosis is based on the histopathologic findings, so a biopsy of the lesion is mandatory. The main histological feature of the metastatic Crohn's disease of the vulva is granulomatous inflammation without caseous necrosis including Langhans giant multinucleated cells.^{4,10} In our case, the diagnosis was supported by the GI manifestations in combination with the histological findings, and exclusion of other granulomatous and infectious disease. As far as treatment of the disease is concerned, recommendations for vulvar Crohn's disease have not been well established, maybe due to unpredictable natural course of disease. While some lesions resolve spontaneously, others fail both medical management and surgical debridement.^{9,11} As far as the treatment

Table 1. Reported cases of Crohn's disease of the vulva (2017-2020)

Reference	Year	Age	GI Sxs	Clinical presentation	Histological findings	Treatment	Follow-up
Pousa-Martinez et al. ¹³	2017	35	+	Symmetric erythema and edema of the genital area and a polyp on the left labia majora	Diffuse lymphocytic inflammatory infiltrate in dermis, noncaseating granulomas	Metronidazole, topical steroids	6 months
Kyriakou et al. ⁴	2019	42	+	Painful bilateral edema and erythema in the vulvar area, periodic bloody or purulent discharge	Chronic inflammation, noncaseating granuloma, multinucleated giant cells in the dermis	Metronidazole, methylprednisolone, azathioprine	>6 months
Bondarenko et al. ¹⁰	2020	47	-	Bilateral asymmetric hypertrophy of the vulva, cone-shaped vegetation resembling condyloma acuminata in the perineal region of the vulva	Small and large lymphoid aggregations and noncaseating histiocytic granulomas with epithelioid cells and Langhans giant multinuclear cells	Antimicrobial, anti-inflammatory, immunomodulating agents	7 years
Present case	2020	43	+	Painless unilateral edema and erythema in the right labia majora of the vulva	Chronic inflammation with a noncaseating granuloma and multinucleated giant cells	Metronidazole, prednisolone, infliximab	>2 months

+: present; -: absent; GI: gastrointestinal; Sxs: symptoms

of the disease is concerned, only a small number of cases with their therapeutic results have been reported. This is probably because of the low incidence of the disease. Kurtzman et al. have reported a therapeutic algorithm for metastatic Crohn's disease.¹² The first-line therapy is considered to be glucocorticosteroids. They can be administered either topically or systematically. In the case of systematic therapy, prednisolone 30 mg/day is the most common effective dosage that has been reported in the literature.¹³ However, the disease is frequently refractory and sustained improvement with any single modality of therapy is rarely seen. As a result, topical steroids are often used in combination with antibiotics and immunosuppressants such as azathioprine and cyclosporine.^{4,14} An immunosuppressant with satisfactory success rate seems to be metronidazole. The recommended dosage is 20 mg/kg/day for at least 12 to 36 months; however, bilateral pedal paresthesia has been reported as a complication in case of long-term use. The introduction of biologic agents, such as anti-tumour necrosis factor (TNF) agents, the past two decades has played an important role in the management of CD. Infliximab is an anti-TNF- α factor that has shown good results when combined with azathioprine or methotrexate, but its use is advocated only after failure of first-line therapy.¹⁴ Surgery is considered to be the last resort in the management of the disease. This is because poor healing is expected in the majority with subsequent recurrence of lesions. Surgery is best used in combination with medical treatments, but if required debridement, local excision, or vulvectomy with skin grafts may be successful.¹⁵

CONCLUSIONS

Crohn's disease of the vulva is a rare entity of extraintestinal manifestations of Crohn's disease and is not promptly recognized. Owing to its diverse clinical features, it could be easily confused with other diseases with similar manifestations and awareness that such involvement may precede GI symptoms must be raised. Only with a high index of suspicion we can achieve a proper diagnosis as well as a successful treatment.

REFERENCES

1. Foo W, Papalas J, Robboy S, et al. Vulvar manifestations of Crohn's disease. *Am J Dermatopathol* 2011; 33(6):588-93.
2. Barret M, de Parades V, Battistella M, et al. Crohn's disease of the vulva. *J Crohns Colitis* 2014; 8(7):563-70.
3. Sides C, Trinidad M, Heitlinger L, et al. Crohn disease and the gynecologic patient. *Obstet Gynecol Surv* 2013; 68(1):51-61.
4. Kyriakou G, Gkermepesi M, Thomopoulos K, et al. Metastatic vulvar Crohn's disease preceding intestinal manifestations: a case report and short review. *Acta Dermatovenereol Alp Pannonica* 2019; 28(3):131.
5. Parks A, Morson B, Pegum J. Crohn's disease with cutaneous involvement. *Proc R Soc Med* 1965; 58(4):241-2.
6. Lkousse MA, Gharbi K, Elfarouki A, et al. Vulvar lesion in Crohn's disease: a new case report. *Gastroenterol Hepatol Open Access* 2019; 2(4):22.
7. Andreani S, Ratnasingham K, Dang H, et al. Crohn's disease of the vulva. *Int J Surg* 2010; 8(1):2-5.
8. Bender-Heine A, Grantham JT, Zaslau S, et al. Metastatic Crohn dis-

- ease: a review of dermatologic manifestations and treatment. *Cutis* 2017; 99(6):E33–E40.
9. Abboud M. Vulvar inflammation as a manifestation of Crohn's disease. *World Journal of Emergency Medicine* 2017; 8(4):305.
 10. Bondarenko K, Dobrokhotova Y, Romyantseva T, et al. Crohn's disease of the vulva: A tough diagnosis (a case report of a 47 y.o. patient). *Clinical Case Reports* 2020; 8(3):563–7.
 11. Shen R, Cybulska B, Thin R, et al. Vulval Crohn's disease mimicking genital herpes. *International Journal of STD & AIDS* 1993; 4(1):54–6.
 12. Kurtzman D, Jones T, Lian F, et al. Metastatic Crohn's disease: A review and approach to therapy. *J Am Acad Dermatol* 2014; 71(4):804–13.
 13. Pousa-Martínez M, Alfageme F, González de Domingo MA, et al. Vulvar metastatic Crohn's disease: clinical, histopathological and ultrasonographic findings. *Dermatol Online J* 2017; 23(11):13030/qt6rd9b8zf.
 14. Ramji A. Isolated vulvo-vaginal Crohn's disease: case report of the rare entity. *International Surgery Journal*. 2019; 6(4):1400.
 15. Rowan D. Crohn's Disease of the Vulva. In: Bornstein J. (eds) *Vulvar Disease*. Springer, Cham: 2019. https://doi.org/10.1007/978-3-319-61621-6_52

Болезнь Крона вульвы: клинический случай

Калиопи Коккали¹, Кристос Явазо¹, Ефтимия Сука², София Лекка¹, Александрус Фотиу¹,
Ейрини Герамани¹, Виктория Псомиаду¹, Георги Воргиас¹

¹ Отделение гинекологической онкологии, Онкологическая больница „Метакса“, Пирей, Греция

² Отделение патологии, Онкологическая больница „Метакса“, Пирей, Греция

Адрес для корреспонденции: Калиопи Коккали, Отделение гинекологической онкологии, Онкологическая больница „Метакса“, „Мпотаси“ № 51, 18537 Пирей, Греция; E-mail: pori.koc@gmail.com; Тел.: 213 2079100

Дата получения: 25 августа 2020 ♦ **Дата приемки:** 6 октября 2020 ♦ **Дата публикации:** 31 декабря 2021

Образец цитирования: Kokkali K, Iavazzo Ch, Souka E, Lekka S, Fotiou A, Geramani E, Psomiadou V, Vorgias G. Crohn's disease of the vulva: a case report. *Folia Med (Plovdiv)* 2021;63(6):990-3. doi: 10.3897/folmed.63.e58002.

Резюме

Болезнь Крона – это мультисистемное хроническое воспалительное заболевание, которое может поражать различные органы, помимо желудочно-кишечного тракта, такие как суставы, сосудистую оболочку и кожу. Болезнь вульвы Крона можно легко спутать с другими гранулематозными заболеваниями, поэтому следует повышать осведомленность о том, что такое поражение может предшествовать желудочно-кишечным симптомам. На сегодняшний день в медицинской литературе описано несколько случаев болезни Крона. Здесь мы сообщаем о случае 43-летней женщины с 6-месячным анамнезом поражения вульвы; чуть более года назад пациенту был поставлен диагноз: болезнь Крона толстой кишки.

Ключевые слова

Болезнь Крона, метастатическая болезнь Крона, неказеозная гранулема, болезнь Крона вульвы