

# Evaluation of Clinical Efficacy of Topical Tacrolimus 0.1% and Clobetasol Propionate 0.05% in Desquamative Gingivitis, Manifestation of Oral Lichen Planus

Lilia Kavlakova<sup>1</sup>

<sup>1</sup> Department of Periodontology and Oral Diseases, Faculty of Dental Medicine, Medical University of Plovdiv, Plovdiv, Bulgaria

**Corresponding author:** Lilia Kavlakova, Department of Periodontology and Oral Diseases, Faculty of Dental Medicine, Medical University of Plovdiv, 3 Hristo Botev Blvd., Plovdiv, Bulgaria; Email: kavlakovi@abv.bg; Tel.: +359 899 357 411

**Received:** 6 Jan 2021 ♦ **Accepted:** 8 Feb 2021 ♦ **Published:** 30 June 2022

**Citation:** Kavlakova L. Evaluation of clinical efficacy of topical tacrolimus 0.1% and clobetasol propionate 0.05% in desquamative gingivitis, manifestation of oral lichen planus. Folia Med (Plovdiv) 2022;64(3):415-421. doi: 10.3897/folmed.64.e62851.

## Abstract

**Introduction:** Oral lichen planus (OLP) is a chronic inflammatory mucocutaneous disorder with unknown etiology. Numerous treatment options have been reported, with topical corticosteroids being very often used as the first-line therapy for gingival lesions. However, a relatively novel therapeutic option is provided by tacrolimus.

**Aim:** To compare the clinical effectiveness of topical tacrolimus 0.1% and clobetasol propionate 0.05% in the management of desquamative gingivitis, a distinct clinical manifestation of OLP.

**Materials and methods:** This comparative study included 20 patients with histologically proven symptomatic OLP with gingival manifestation. The participants were divided into 2 groups: group A (clobetasol propionate 0.05% cream) and group B (topical tacrolimus 0.1% ointment). They were instructed to apply topical medications twice daily for three consecutive weeks. Custom trays have been used for better drug delivery. The patients were recalled at 1, 2, and 3 months after cessation of therapy for a follow-up control of any relapse.

**Results:** The subjects in both groups showed a significant reduction in the burning sensation/pain and discomfort according to the visual analog scale (VAS). Similarly, both groups showed reduction in the efficiency index, and moderate improvement especially was seen in the tacrolimus 0.1% group (53%) and the clobetasol propionate group 0.05% (47%). Patients treated with clobetasol propionate 0.05% didn't have a relapse at 2 and 3 months after cessation of treatment. In contrast, 30% of the patients treated with tacrolimus 0.1% had a relapse of the condition at 2 and 3 months.

**Conclusions:** Tacrolimus can be considered as a good alternative topical medication in the treatment of OLP, especially in those patients that do not respond to topical corticosteroids.

## Keywords

clobetasol propionate, desquamative gingivitis, oral lichen planus, tacrolimus

## INTRODUCTION

Lichen planus (LP) is a relatively common, chronic mucocutaneous inflammatory and presumably autoimmune disease that affects about 1% to 2% of the general population with a predilection for females and a mean age at onset in the fourth to fifth decade.<sup>[1]</sup> Lichen planus can affect the skin, mucous membranes, nails and hair. All regions of the oral cavity may be affected; however, most commonly, lesions are found on the posterior buccal mucosa and, in order of decreasing frequency, the gingiva, tongue, palate, lip, and floor of the mouth.<sup>[2]</sup> The gingiva may be the only site of involvement in about 10% of the cases, clinically manifest as desquamative gingivitis. Desquamative gingivitis is a descriptive clinical term, not an entity. Although the term has remained over the years, to date we know that the latter can be a clinical presentation of different systemic diseases and conditions. The clinical sign and symptoms are due to different histological phenomena (atrophy, erosion, etc.), not desquamation. Clinical presentations of OLP vary and appear in at least six forms: reticular, popular, plaque like, atrophic, erosive, and bullous lesions that can occur separately or simultaneously.<sup>[2,3]</sup> The erosive, atrophic, and bullous forms are the most symptomatic forms of OLP and can cause symptoms ranging from spontaneous soreness to severe pain interfering with eating, speech and swallowing.<sup>[4]</sup>

Although many options for the treatment of symptomatic OLP are available, no therapy is curative.<sup>[4,5]</sup> To date, the most frequently described therapy for OLP is the administration of topical corticosteroids as first-line of treatment.<sup>[6,7]</sup>

A range of other treatments have been reported, including topical and systemic retinoids, topical cyclosporine, oral dapsone, tetracycline, levamisole, anti-malarials, azathioprine, enoxaparin, thalidomide, photochemotherapy, LLLT, oral PUVA, plant-derived substances, and surgery, all with variable outcomes.<sup>[8]</sup>

OLP is frequently resistant to topical corticosteroids, thereby prompting trials of new therapeutic modalities with less morbidity and fewer side effects. Recent studies have shown that tacrolimus ointment 0.1% is an efficacious and well-tolerated topical therapy in treating symptomatic lesions of OLP that causes few local side effects.<sup>[9,10]</sup>

The greatest problem of using topical corticosteroids and tacrolimus in the mouth is how to make them adhere to the gingiva for a sufficient time. Therefore for the purpose of the present study, we fabricated individual custom trays.<sup>[11]</sup> The data collected from this clinical study can move us closer to implementing a specific treatment plan for desquamative gingivitis, manifestation of OLP.

## AIM

To compare the clinical effectiveness of topical clobetasol propionate 0.05% and tacrolimus 0.1% in the management of desquamative gingivitis, a manifestation of OLP.

## MATERIALS AND METHODS

### Patient selection and evaluation

Twenty patients with clinically and histologically confirmed OLP were included in the study. All subjects had desquamative gingivitis resulting from an atrophic or erosive form of OLP. The bullous form of OLP wasn't included because intraoral bullae are rare and rupture very fast, leaving erosive lesions. The inclusion criteria were: patients who gave a signed informed consent, and patients with symptoms, i.e. pain and burning sensation, secondary to oral lichen planus. The exclusion criteria included: topical or systemic medication for treatment of OLP 1 month prior to the study, patients with a known allergy or contraindication to study medications, patients with findings of any physical or mental abnormality, pregnancy or lactating period, histopathological examination with atypical or dysplastic features.

### Study design and medications

The participants were divided into 2 groups as group A (using clobetasol propionate 0.05% cream, Dermovate 0.05%) and group B (topical tacrolimus 0.1% ointment, Protopic 0.1%). Participants were instructed to apply the topical medications twice daily, 20 minute each time after oral hygiene for three consecutive weeks. Custom trays were used to achieve better drug delivery. The therapeutic plan of treatment was approved by the Ethics Committee of the Medical University of Plovdiv (No. 4/12.12.2019).

The severity of pain and discomfort was assessed on a VAS scale at baseline and at 3 weeks after cessation of treatment, where 0 indicated no pain and 10 - the worst possible pain. The patients were asked to mark VAS at a point which best represented the level of symptoms. The symptoms data were then scored according to the following classification: score 0: without pain/discomfort (VAS=0); score 1: mild pain/discomfort (0<VAS<3.5); score 2: moderate pain/discomfort (3.5<VAS<7); score 3: severe pain/discomfort (7<VAS<10).

Mutafchieva's efficiency index was used<sup>[8]</sup>, modified by the author to be used for evaluation of gingival lesions. Treatment efficacy index (EI) was calculated, using the following formula:

$$EI = \frac{TSO - TSI}{TSO} \times 100,$$

where TSO is the total score of the lesion before treatment, and TSI - the total score of the lesion after treatment. TSO and TSI were calculated as follows: the gingiva was divided into 3 segments (right posterior, anterior, and left posterior segments), scores were made on vestibular and oral surfaces (i.e. a total of 6 segments for every jaw). For every segment, the worst score according to Thongprasom scale was recorded.<sup>[12]</sup> The efficacy index was categorized into a 5 rank

scale as follows: healed: EI=100%; marked improvement:  $75\% \leq EI < 100\%$ , moderate improvement  $25\% \leq EI < 75\%$ , mild improvement  $0\% \leq EI < 25\%$ , and no improvement EI=0. The patients were recalled at 1, 2, and 3 months after cessation of therapy for a follow-up occurring relapse.

## Statistical analysis

Statistical analyses were performed using the IBM SPSS software program, version 26 (2018) and Minitab version 19 (2019). The demographic data are presented as mean  $\pm$  SD. The statistical analysis included tracking the dynamics of target indicators in each of two groups and between them. Proportional comparisons were analysed by Fisher's exact test. Intergroup comparisons included a *t*-test for two independent samples, cross-tabulations, and the chi-squared test. The results were interpreted as significant at  $p < 0.05$ .

## RESULTS

Twenty patients (18 women and 2 men) with atrophic and erosive gingival form of OLP participated in the study. The patients in both groups were matched in age, gender, and clinical form of OLP (Table 1).

Similar to other studies, the disease distribution was seen more frequently in women (90% of all participants). According to the form of OLP, 50% of the subjects had an erosive form and 50% had an atrophic form of OLP.

Ten patients (9 women and 1 man) received clobetasol propionate 0.05% (group A) and 10 patients (9 women and 1 man) received tacrolimus 0.1% (group B). Before starting therapy, the average scores of the pain/discomfort, according to the VAS scale were  $7.80 \pm 1.22$  and  $6.70 \pm 3.02$  in groups

A and B, respectively. There was no statistically significant difference between the two groups ( $p=0.300$ ). Reduction of the mean scores of VAS was observed in both groups at the end of week 3 after cessation the therapy. Patients treated with clobetasol propionate showed 57% reduction in the VAS score ( $3.30 \pm 1.94$ ) and those in tacrolimus group - 74% ( $1.70 \pm 1.76$ ). Although the tacrolimus group showed a higher level of improvement of the VAS score (17% compared to the clobetasol propionate group, the difference failed to reach statistical significance) ( $p=0.435$ ) (Fig. 1).

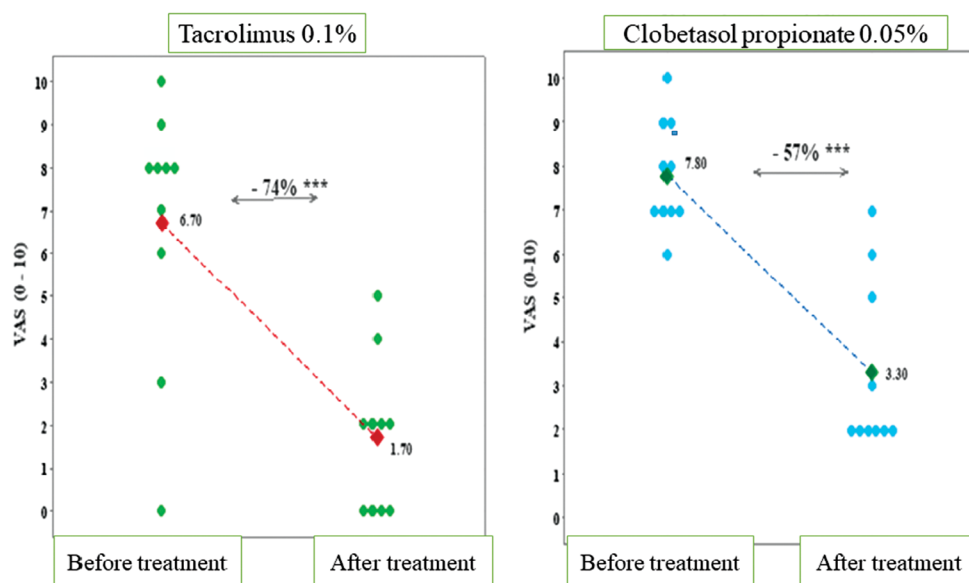
The changes in treatment efficacy index recorded in patients which apply topical clobetasol propionate 0.05% (group A) weren't significantly greater than those of group B treated with topical tacrolimus 0.1% ( $p=0.587$ ). However, most of the participants in both group showed moderate improvement as follows: seven of the 10 patients treated with clobetasol propionate 0.05% (70%) and eight of the patient (80%) using topical tacrolimus 0.1%, respectively. We observed significant improvement in 20% in both treated group (2 patients in the clobetasol propionate 0.05% group and 2 in the tacrolimus group). Only one patient in the clobetasol propionate 0.05% group showed slight improvement (Fig. 2).

In addition, the author analysed the interaction between treatment efficacy index and clinical form of OLP (atrophic/erosive). After collected information was sorted and tabulated, we observed equal distribution of the patients treated with tacrolimus 0.1% ointment according to the efficacy index and form of the OLP ( $p=1.000$ ). Whereas in the clobetasol propionate 0.05% group, we noted slight improvement in one patient with atrophic form (20%), moderate improvement in 4 patients (80%) with atrophic form and 3 patients (60%) with erosive form, significant improvement in 2 patients with erosive form (40%), ( $p=0.208$ ) (Table 2). Complete remission was not seen in both groups. However,

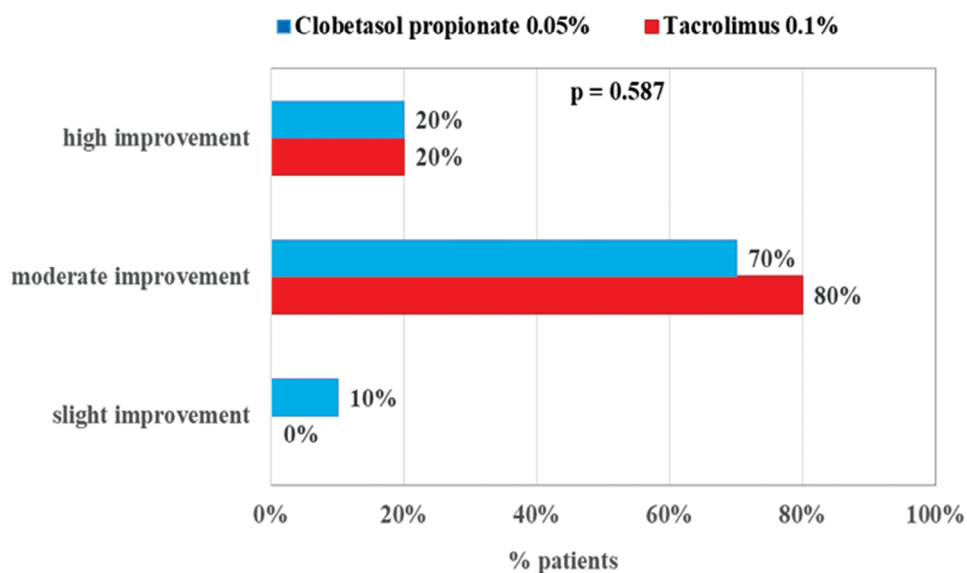
**Table 1.** Demographics of both groups of patients

Values	Treatment type		Significance
	Tacrolimus 0.1% ointment	Clobetasol propionate 0.05% cream	<i>p</i>
Gender (N, %)			
- Female	9 (90%)	9 (90%)	1.00 <sup>f</sup>
- Male	1 (10%)	1 (10%)	
OLP form (N, %)			
- erosive	5 (50%)	5 (50%)	1.00 <sup>f</sup>
- atrophic	5 (50%)	5 (50%)	
Age (N, %)			
- 31-40 years	1 (10%)	3 (30%)	0.321 <sup>c</sup>
- 41-50 years	3 (30%)	2 (20%)	
- 51-60 years	5 (50%)	3 (30%)	
- >61 years	3 (30%)	3 (30%)	
VAS (at baseline) (Mean $\pm$ SD)	$6.70 \pm 3.02$	$7.80 \pm 1.22$	0.300 <sup>t</sup>

<sup>f</sup>: Fisher's test; <sup>c</sup>: chi-square test; <sup>t</sup>: the *t*-test for two independent samples



**Figure 1.** Changes in VAS before treatment and immediately after cessation of treatment.



**Figure 2.** Distribution of patients by treatment efficacy.

**Table 2.** Interaction between efficacy index and form of OLP

OLP form	Treatment type			
	Tacrolimus 0.1% ointment	<i>p</i>	Clobetasol propionate 0.05% cream	<i>p</i>
Slight improvement				
- atrophic	0 (0%)		1 (20%)	
- erosive	0 (0%)		0 (0%)	
Moderate improvement				
- atrophic	4 (80%)	1.000	4 (80%)	0.208
- erosive	4 (80%)		3 (60%)	
Significant improvement				
- atrophic	1 (20%)		0 (0%)	
- erosive	1 (20%)		2 (40%)	

there was no statistically significant difference between efficacy index and form of OLP in both treated group.

There were no dropouts in the current study. Two of the patients (20%) treated with topical tacrolimus 0.1% reported adverse effects (stomach discomfort), whereas no one in clobetasol propionate 0.05% group announced any side effects.

The percentage of recurrence per treatment at 1, 2, and 3 months is presented in **Fig. 3**. In 20% of the topical tacrolimus-treated patients occurred relapse and 30% of the patients in clobetasol propionate group on the first month after cessation the therapy. At 2 months no recurrence was seen in both groups, while at the end of month 3, 30% of the subjects in the tacrolimus group showed relapse. Interestingly, no one of the participants in the clobetasol propionate group had a relapse.

## DISCUSSION

This study is the first clinical trial in Bulgaria which aimed at evaluating the effectiveness and compliance of the administration of 0.1% topical tacrolimus and clobetasol propionate 0.05% for treatment of gingival lesions of OLP using custom trays for better drug delivery. Treatment of symptomatic OLP is a therapeutic challenge. Despite numerous existing treatment modalities, there are many treatment failures.

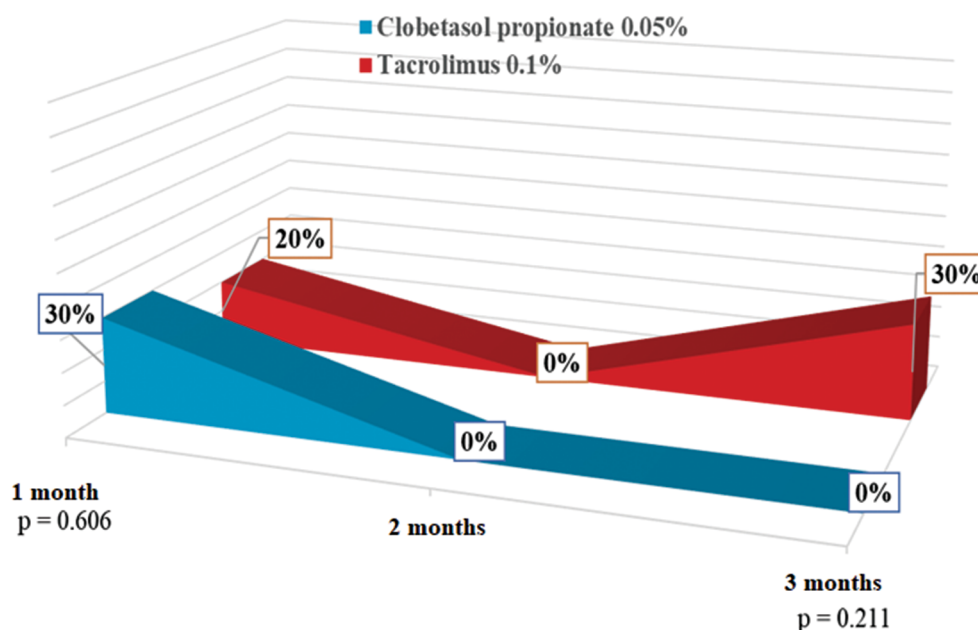
Our results show a similar degree of efficacy in both treated group in terms of pain and discomfort reduction, efficacy index, and very low recurrence rates. Although tacrolimus ointment is available in 2 strengths, 0.1% and 0.03%, the 0.1% formulation has shown to be more effective in treating OLP. Topical tacrolimus 0.1% ointment induced

better initial therapeutic response according to the VAS scale than the clobetasol propionate 0.05% cream did. Similar results were documented by Revanappa et al.<sup>[13]</sup> The higher reduction in the VAS scores seen in the tacrolimus group may be due to the drug's inhibitory effect on the activation and proliferation of T lymphocytes, while the relief seen in the clobetasol propionate group can be attributed to the local anti-inflammatory and anti-immunological properties of the drug in suppressing the T-cell function.<sup>[14]</sup> In both types of topical treatment, moderate to significant improvement was achieved. However, patients treated with clobetasol propionate 0.05% didn't have a relapse 2 and 3 months after discontinuation of the treatment. Therefore, use of topical clobetasol propionate shows a more stable effect over time. This was supported by another study done by Radfar et al.<sup>[15]</sup> who reported that clobetasol propionate 0.05% ointment was found to be more useful than tacrolimus 0.1% in the treatment of OLP. This is in contrast to the study done by Lodi et al.<sup>[16]</sup> who found tacrolimus to be as useful as clobetasol in the treatment of OLP.

In the present study, two of the patients (20%) treated with topical tacrolimus 0.1% reported adverse effects (stomach discomfort), whereas no one in the clobetasol propionate 0.05% group reported any side effects. Other similar studies reported that one-third of the patients treated with tacrolimus complained of adverse effects at the site of application.<sup>[17]</sup>

## CONCLUSIONS

Future research can be directed at assessing the possible relationship between the form of OLP, the efficacy index, and the occurrence of relapses in patients treated with both



**Figure 3.** Percentage of recurrence at 1, 2, and 3 months of treatment.

topical medications. Hence, tacrolimus can be considered as a good alternative topical medication in the treatment of OLP, especially in those patients that do not respond to topical corticosteroids.

## REFERENCES

1. Ismail SB, Kumar SKS, Zain RB. Oral lichen planus and lichenoid reactions: etiopathogenesis, diagnosis, management and malignant transformation. *J Oral Sci* 2007; 49(2):89–106.
2. Eisen D, Carrozzo M, Sebastian JVB, et al. Oral lichen planus: Clinical features and management. *Oral Dis* 2005; 11:338–49.
3. Lodi G, Scully C, Carrozzo M, et al. Current controversies in oral lichen planus: report of an international consensus meeting. Part 2. Clinical management and malignant transformation. *Oral Surg Oral Med Oral Pathol Oral Radiol Endod* 2005; 100:164–78.
4. Cribier B, Frances C, Chosidow O. Treatment of lichen planus: an evidence-based medicine analysis of efficacy. *Arch Dermatol* 1998; 134:1521–30.
5. Carrozzo M, Gandolfo S. The management of oral lichen planus. *Oral Dis* 1999; 5(3):196–205.
6. Thongprasom K, Luangjarmekorn L, Sererat T, et al. Relative efficacy of flucinolone acetonide compared with triamcinolone acetonide in treatment of oral lichen planus. *J Oral Pathol Med* 1992; 21:456–8.
7. Laeijendecker R, Tank B, Dekker SK, et al. A comparison of treatment of oral lichen planus with topical tacrolimus and triamcinolone acetonide ointment. *Acta Derm Venereol* 2006; 86(3):227–29.
8. Mutafchieva M. [Immunobiological effects of low-level laser therapy (LLLT) in the treatment of oral lichen planus. Experimental, laboratory and clinical studies.] [PhD thesis]. Plovdiv: Medical University of Plovdiv; 2018 [Bulgarian].
9. Lener E, Brieva J, Schacter M, et al. Successful treatment of erosive lichen planus with topical tacrolimus. *Arch Dermatol* 2001; 137:419–22.
10. Rozycki TW, Rogers III RS, Pittelkow MR, et al. Topical tacrolimus in the treatment of symptomatic oral lichen planus: a series of 13 patients. *J Am Acad Dermatol* 2002; 46:27–34.
11. Aufdemorte TB, De Villez RL, Parel SM. Modified topical corticosteroid therapy for the treatment of oral mucous membrane pemphigoid. *Oral Surg Oral Med Oral Pathol* 1985; 59:256–60.
12. Thongprasom K, Luangjarmekorn L, Sererat T, et al. Relative efficacy of fluocinolone acetonide compared with triamcinolone acetonide in treatment of oral lichen planus. *J Oral Pathol Med* 1992; 21:456–8.
13. Revanappa MM, Naikmasur VG, Sattur AP. Evaluation of efficacy of tacrolimus 0.1% in Orabase and triamcinolone acetonide 0.1% in Orabase in the management of symptomatic oral lichen planus. Randomized single blind control study. *J Indian Acad Oral Med Radiol* 2012; 24(4):269–73.
14. Byrd JA, Davis MDP, Bruce AJ, et al. Response of oral lichen planus to topical tacrolimus in 37 patients. *Arch Dermatol* 2004; 140:1508–12.
15. Radfar L, Wild RC, Suresh L. A comparative treatment study of topical tacrolimus and clobetasol in oral lichen planus. *Oral Surg Oral Med Oral Pathol Oral Radiol Endod* 2008; 105:187–93.
16. Lodi G, Giuliani M, Majorana A, et al. Lichen planus and hepatitis C virus: A multicentre study of patients with oral lesions and a systematic review. *Br J Dermatol* 2004; 151:1172–81.
17. Hodgson TA, Sahni N, Kaliakatsu F, et al. Long-term efficacy and safety of topical tacrolimus in the management of ulcerative/erosive lichen planus. *Eur J Dermatol* 2003; 13:466–70.

# Оценка клинической эффективности местного такролимуса 0.1% и клобетазола пропионата 0.05% при десквамативном гингивите, проявлении красного плоского лишая полости рта

Лилия Кавлакова<sup>1</sup>

<sup>1</sup> Кафедра пародонтологии и заболеваний слизистой оболочки полости рта, Факультет дентальной медицины, Медицинский университет – Пловдив, Пловдив, Болгария

**Адрес для корреспонденции:** Лилия Кавлакова, Кафедра пародонтологии и заболеваний слизистой оболочки полости рта, Факультет дентальной медицины, Медицинский университет – Пловдив, бул. „Христо Ботев“ № 3, Пловдив, Болгария; Email: kavlakovi@abv.bg; Тел.: +359 899 357 411

**Дата получения:** 6 января 2021 ♦ **Дата приемки:** 8 февраля 2021 ♦ **Дата публикации:** 30 июня 2022

**Образец цитирования:** Kavlakova L. Evaluation of clinical efficacy of topical tacrolimus 0.1% and clobetasol propionate 0.05% in desquamative gingivitis, manifestation of oral lichen planus. Folia Med (Plovdiv) 2022;64(3):415-421. doi: 10.3897/folmed.64.e62851.

## Резюме

**Введение:** Красный плоский лишай полости рта (КПЛПР) представляет собой хроническое воспалительное заболевание кожи и слизистых оболочек с неизвестной этиологией. Сообщалось о многочисленных вариантах лечения, при этом местные кортикостероиды очень часто использовались в качестве терапии первой линии при поражениях дёсен. Тем не менее, такролимус обеспечивает относительно новый терапевтический вариант.

**Цель:** Сравнить клиническую эффективность местного такролимуса 0.1% и клобетазола пропионата 0.05% при лечении десквамативного гингивита, явного клинического проявления КПЛПР.

**Материалы и методы:** В сравнительное исследование были включены 20 пациентов с гистологически доказанным симптоматическим КПЛПР с десневыми проявлениями. Участники были разделены на 2 группы: группа А (крем клобетазола пропионата 0.05 %) и группа Б (мазь такролимуса 0.1 % для местного применения). Они были проинструктированы применять местные лекарства два раза в день в течение трёх недель подряд. Специальные ложки использовались для лучшего применения лекарств. Пациенты были приглашены на осмотр через 1, 2 и 3 месяца после прекращения терапии для последующего контроля любого рецидива.

**Результаты:** У субъектов обеих групп наблюдалось значительное уменьшение ощущения жжения/боли и дискомфорта по визуальной аналоговой шкале (ВАШ). Точно так же обе группы показали снижение индекса эффективности, и умеренное улучшение особенно наблюдалось в группе такролимуса 0.1% (53%) и группе клобетазола пропионата 0.05% (47%). У пациентов, получавших клобетазола пропионат 0.05%, рецидивов через 2 и 3 месяца после прекращения лечения не было. Напротив, у 30% пациентов, получавших такролимус 0.1%, через 2 и 3 месяца наблюдался рецидив заболевания.

**Заключение:** Такролимус можно рассматривать как хорошую альтернативу местным препаратам при лечении КПЛПР, особенно у тех пациентов, которые не реагируют на местные кортикостероиды.

## Ключевые слова

клобетазола пропионат, десквамативный гингивит, красный плоский лишай, такролимус