

# Developmental Venous Anomaly Causing Obstructive Hydrocephalus Due to Aqueductal Stenosis: a Case Report

Stefan Bogovski<sup>1</sup>, Kristina Sirakova<sup>2</sup>, Alexander Sirakov<sup>1</sup>, Georgi Vladev<sup>1</sup>, Stanimir Sirakov<sup>1</sup>

<sup>1</sup> Radiology Department, St Ivan Rilski University Hospital, Sofia, Bulgaria

<sup>2</sup> Radiology Department, Alexandrovska University Hospital, Sofia, Bulgaria

**Corresponding author:** Stanimir Sirakov, Radiology Department, St Ivan Rilski University Hospital, Sofia, Bulgaria; Email: ssirakov@bsunivers.com; Tel.: +359 888 755 025

**Received:** 18 Mar 2021 ♦ **Accepted:** 5 May 2021 ♦ **Published:** 31 Oct 2022

**Citation:** Bogovski S, Sirakova K, Sirakov A, Vladev G, Sirakov S. Developmental venous anomaly causing obstructive hydrocephalus due to aqueductal stenosis: case report. *Folia Med (Plovdiv)* 2022;64(5):829-833. doi: 10.3897/folmed.64.e66107.

## Abstract

Cerebral developmental venous anomalies are asymptomatic benign cerebrovascular malformations that are commonly found accidentally on brain magnetic resonance imaging. It is not uncommon for cerebrospinal fluid flow to be obstructed at the level of the aqueduct of Sylvius, causing an obstructive non-communicating hydrocephalus. Most notable reasons for such an obstruction at that level are tumors, congenital etiology, or post-inflammatory gliotic atresia.

Herein we present the case of a 65-year-old male patient with an unusual symptomatic developmental venous anomalies causing stenosis and obstruction of the aqueduct of Sylvius at the level of the mesencephalon. Features of this case are discussed together with its implications, including recognizing, diagnosing, and treating such a finding.

## Keywords

aqueductal stenosis, developmental venous anomaly, hydrocephalus, MRI, DSA

## INTRODUCTION

Cerebral developmental venous anomalies (DVA) are common asymptomatic benign lesions that are usually discovered incidentally at brain magnetic resonance imaging (MRI) examinations.<sup>[1,2]</sup> These lesions correspond to an anatomical variation of the cerebral venous system.<sup>[3]</sup> Obstructive hydrocephalus results secondary to obstruction along the cerebrospinal fluid (CSF) pathway between lateral ventricles at the third/fourth ventricle. It is common for intraventricular cerebrospinal fluid flow to become obstructed at the level of the aqueduct of Sylvius. The obstruction may be caused by a tumor, congenital etiology, or post-inflammatory gliotic atresia, among other conditions.<sup>[4]</sup> Hydrocephalus caused by compression from aqueductal DVA is a rare phenomenon and only a limited num-

ber of cases have been previously published.<sup>[5]</sup> We present a rare case of an obstructive hydrocephalus secondary to aqueductal stenosis caused by DVA and its cross sectional radiological characteristic.

## CASE REPORT

A 65-year-old male patient had undergone an operation for removal of a conjunctival squamous cell carcinoma of his right orbit. Several months later, a local recurrence of the tumor was observed and he was scheduled for a second operation. After a computer tomography (CT) examination of the head, prior to the procedure, hydrocephalus and suspected contusion zones were observed in the brain. The patient had no recollection of a head injury. Neurological

examination showed locomotor ataxia, weak to missing eyesight in his right eye, dementia episodes, hydrocephalic syndrome, and urinary and bowel incontinence.

The patient was admitted to the Neurosurgery Department of our hospital for further evaluation and eventual treatment of the findings. The MRI of the brain we conducted after admitting the patient showed tri-ventriculomegaly with a normal-sized fourth ventricle. An abnormal vascular finding, corresponding to a DVA, running anteriorly posteriorly through the mesencephalon and tectum mesencephali was observed. In its trajectory, the DVA was compressing the aqueduct of Sylvius and then draining into the vein of Galen (Fig. 1).

A digitally subtracted angiography was performed showing radially converging venous vessels ventrally from the vein of Galen - an image corresponding to the finding in the MRI sequences (Fig. 2).

## DISCUSSION

Aqueductal stenosis from vascular lesions is a rare entity. Cerebral vascular anomalies including developmental venous anomalies, venous anomaly, vein of Galen aneurysm, ecstasic arteries, dilated abnormal veins, and arteriovenous malformation can cause mechanical compression and hence obstructive hydrocephalus requiring CSF diversion procedures.<sup>[6]</sup> Developmental venous anomaly, formerly known as venous malformation, medullary venous malformation, or venous angioma is one of the commonest vascular malformations within the brain.<sup>[7]</sup> They are composed of dilated centripetally draining medullary veins and merge into a collecting transcerebral vein that opens into either superficial subcortical veins or subependymal veins, thus forming the so-called caput medusa.<sup>[8]</sup> In addition, they have no proliferative potential and no direct arteriovenous shunts. Normal brain tissue is situated between the dilated veins. Although the etiology is still under debate, they are generally accepted to result from aplasia, hypoplasia, or early occlusion of normally developing veins between Padgett's fourth and seventh stages.<sup>[9]</sup> They are considered as compensatory venous systems developing because of absence of normal veins.

DVAs are among the most common intracranial vascular malformations. They occur in up to 5% of the general population and are usually asymptomatic. However, in very rare circumstances, a DVA can impede the CSF flow through the cerebral aqueduct and become symptomatic.<sup>[6]</sup> Mechanical complications can be caused by direct compression of neural structures, typically by the draining collector. An example of such unique complication is reflected in our patient in whom the DVA was anatomically located on the proximal aqueduct. For the small subset of DVAs that are symptomatic, other vascular malformations are often concurrently present.<sup>[10]</sup> Conversely, DVAs in the aqueductal region have been reported to lack this typical association with other vascular malformations.<sup>[11]</sup>

Nonetheless, regardless of location, an intervention targeting symptomatic DVAs should be avoided.<sup>[12,13]</sup> Removal of such DVA confers a risk of developing regional venous congestion because of the extraordinary angioarchitecture, frequently leading to venous infarction of the surrounding normal brain.<sup>[2,14]</sup> In congruence with the recommendations for avoiding intervention to DVAs, even for these lesions obstructing the aqueduct, the safe treatment option is via the CSF diversion for the hydrocephalus.<sup>[15]</sup> Endoscopic third ventriculostomy (ETV) was successfully performed in our patient in accordance with the clinical and radiological findings. In our experience, this therapeutic approach is currently considered the treatment of choice for obstructive hydrocephalus. The successfully conducted procedure creates an alternative CSF flow pathway that bypasses the obstruction at the level of the mesencephalon. Improved CSF drainage and ventricle size is to be expected right after the neurosurgical intervention thus rendering the patient fit for the following possible curative management of the orbital mass.

## CONCLUSIONS

DVAs are mostly asymptomatic in nature; however, some studies have reported those with various neurological symptoms that can be progressing into debilitating morbidity if not properly treated. In rare cases with obstructive hydrocephalus following aqueductal stenosis, CSF diversion may be helpful and endoscopic third ventriculostomy should be considered as an effective and safe treatment modality.

## Acknowledgements

The authors have no support to report.

## Funding

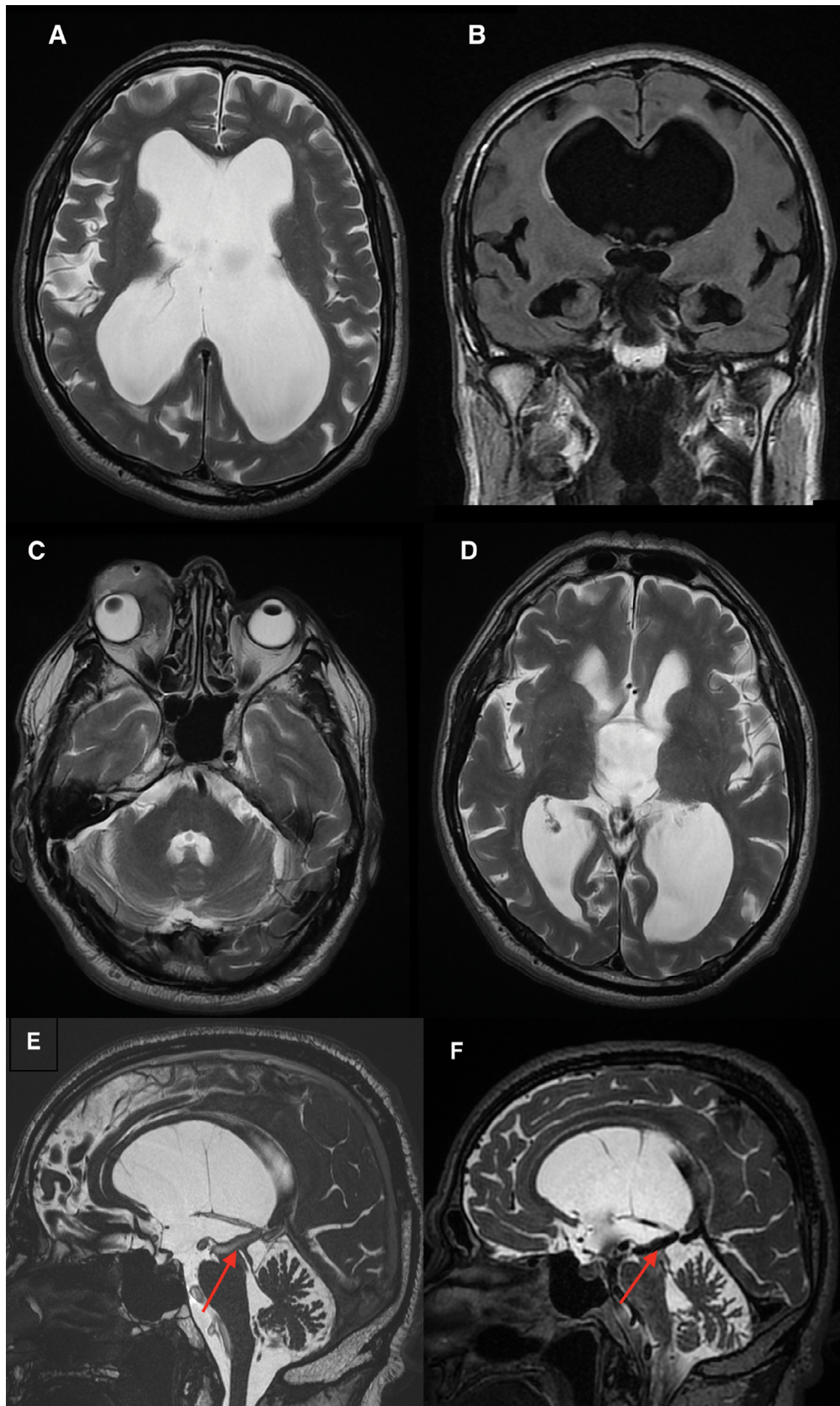
The authors have no funding to report.

## Competing Interests

The authors have declared that no competing interests exist.

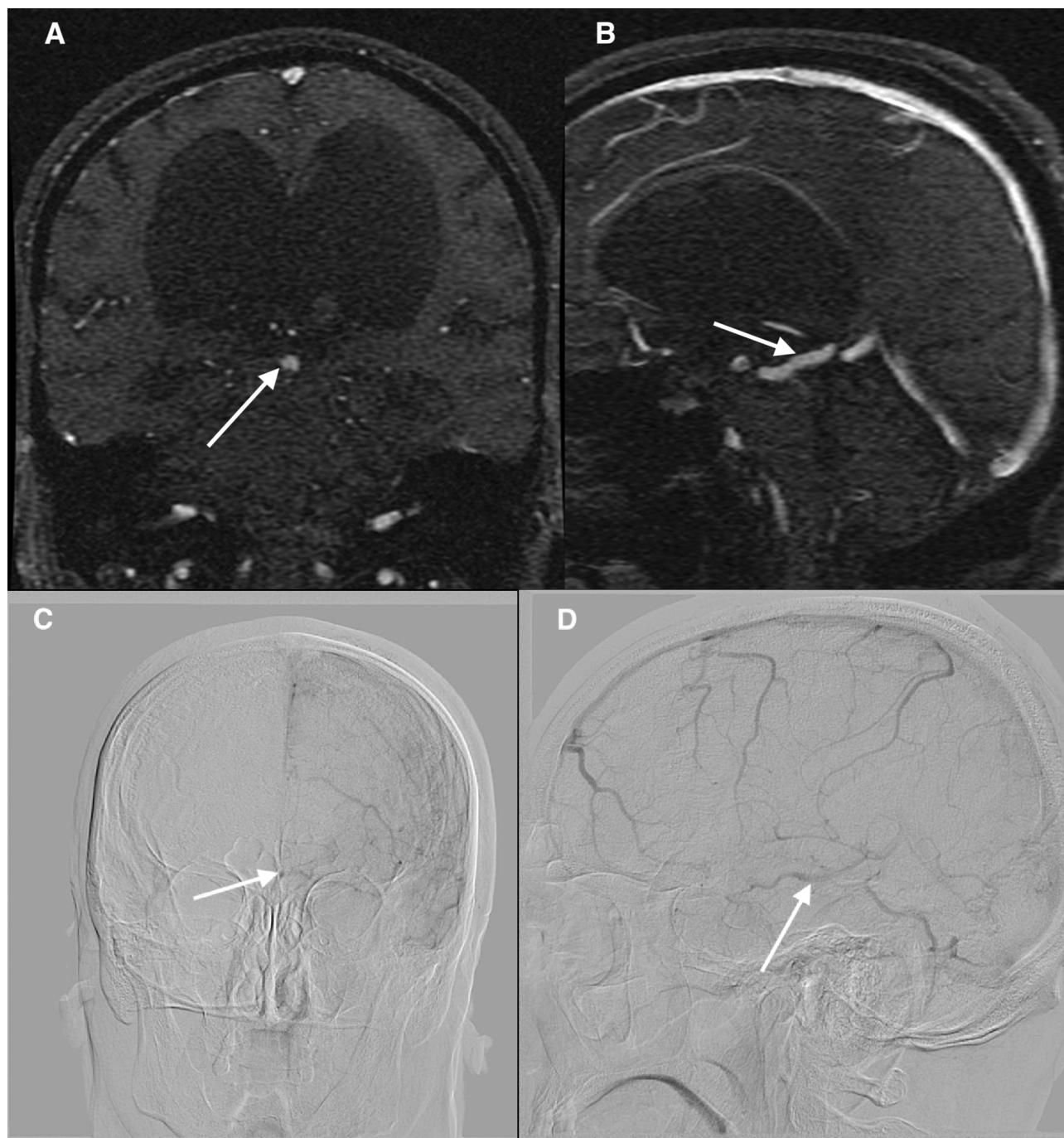
## Author contributions

S.B., A.S., and G.V. wrote the manuscript and obtained the images; K.S. and S.S. critically reviewed the manuscript and did the final revision of the manuscript.



**Figure 1.** MRI demonstrates obstructive non-communicating hydrocephalus. (A) Both lateral and third ventricles are abnormally dilated; (B) The fourth ventricle appears to be of normal dimensions; (C) Residual orbital mass of the right eye could also be noted. Periventricular lucency around both lateral ventricles was also documented on the axial T2 weighted images. Based on the flow-void artifacts, a prominent and dilated vascular structure was detected, running anteriorly posteriorly through the mesencephalon and the aqueduct of Sylvius (E, F, red arrows).





**Figure 2.** MRI non-contrast venography confirmed the presence of an abnormal venous structure draining into the vein of Galen (A, B, white arrows). Digitally subtracted angiography (venous phase) confirmed the MRI finding suggesting a DVA of the mesencephalon running posteriorly with a prominent drainage to the vein of Galen (C, D, white arrows). There was no diffuse capillary stain, abnormal venous disposition or arterial-venous shunting observed of the selective angiography from the left internal carotid artery.

## REFERENCES

1. Cavallo C, Faragò G, Broggi M, et al. Developmental venous anomaly as a rare cause of obstructive hydrocephalus. *J Neurosurg Sci* 2015; 63(5):600–6.
2. Guhl S, Kirsch M, Lauffer H, et al. Unusual mesencephalic developmental venous anomaly causing obstructive hydrocephalus due to aqueductal stenosis: Case report. *J Neurosurg Pediatr* 2011; 8(4):407–10.
3. Hanson EH, Roach CJ, Ringdahl EN, et al. Developmental venous anomalies: appearance on whole-brain CT digital subtraction angiography and CT perfusion. *Neuroradiology* 2011; 53(5):331–41.
4. Jellinger G. Anatomopathology of non-tumoral aqueductal stenosis. *J Neurosurg Sci* 1986; 30(1-2):1–16.
5. Paulson D, Hwang SW, Whitehead WE, et al. Aqueductal developmental venous anomaly as an unusual cause of congenital hydrocephalus: a case report and review of the literature. *J Med Case Reports* 2012; 6(1):7.

6. Pereira VM, Geibprasert S, Krings T, et al. Pathomechanisms of symptomatic developmental venous anomalies. *Stroke* 2008; 39(12):3201–15.
7. Rammos SK, Maina R, Lanzino G. Developmental venous anomalies: current concepts and implications for management. *Neurosurgery* 2009; 65(1):20–30.
8. Blackmore CC, Mamourian AC. Aqueduct compression from venous angioma: MR findings. *Am J Neuroradiol* 1996; 17(3):458–60.
9. Kuo K-L, Tsai F-J, Liu Y-J, et al. Unusual location of developmental venous anomaly within fourth ventricle causing obstructive hydrocephalus – a case report. *Neurologia i Neurochirurgia Polska* 2018; 52(1):112–5.
10. Ruiz DSM, Yilmaz H, Gailloud P. Cerebral developmental venous anomalies: Current concepts. *Ann Neurol* 2009; 66(3):271–83.
11. Yagmurlu B, Fitoz S, Atasoy C, et al. An unusual cause of hydrocephalus: aqueductal developmental venous anomaly. *Eur Radiol* 2005; 15(6):1159–62.
12. Pryor J, Setton A, Berenstein A. Venous anomalies and associated lesions. *Neurosurg Clin N Am* 1999; 10(3):519–25.
13. Aagaard BDL, Song JK, Eskridge JM, et al. Complex right hemisphere developmental venous anomaly associated with multiple facial hemangiomas: Case report. *J Neurosurg* 1999; 90(4):766–9.
14. Aoki R, Srivatanakul K. Developmental venous anomaly: benign or not benign. *Neurol Med Chir (Tokyo)* 2016; 56(9):534–43.
15. Oka K, Kumate S, Kibe M, et al. Aqueductal stenosis due to mesencephalic venous malformation: Case report. *Surg Neurol* 1993; 40(3):230–5.

## Венозная аномалия развития, вызывающая обструктивную гидроцефалию из-за акведукального стеноза: клинический случай

Стефан Боговски<sup>1</sup>, Кристина Сиракова<sup>2</sup>, Александр Сираков<sup>1</sup>, Георги Владев<sup>1</sup>, Станимир Сираков<sup>1</sup>

<sup>1</sup> Отделение радиологии, УМБАЛ „Св. Иван Рилски“, София, България

<sup>2</sup> Отделение радиологии, УМБАЛ „Александровска“, София, България

**Адрес для корреспонденции:** Станимир Сираков, Отделение радиологии, УМБАЛ „Св. Иван Рилски“, София, България; Email: ssirakov@bsunivers.com; Тел.: +359 888 755 025

**Дата получения:** 18 марта 2021 ♦ **Дата приемки:** 5 мая 2021 ♦ **Дата публикации:** 31 октября 2022

**Образец цитирования:** Bogovski S, Sirakova K, Sirakov A, Vladov G, Sirakov S. Developmental venous anomaly causing obstructive hydrocephalus due to aqueductal stenosis: case report. *Folia Med (Plovdiv)* 2022;64(5):829–833. doi: 10.3897/folmed.64.e66107.

### Резюме

Цереброваскулярные венозные аномалии развития (ЦВА) представляют собой бессимптомные доброкачественные цереброваскулярные мальформации, которые обычно обнаруживаются случайно при магнитно-резонансной томографии (МРТ) головного мозга. Нередки случаи, когда поток спинномозговой жидкости затруднен на уровне синдвиева водопровода, вызывая обструктивную несообщающуюся гидроцефалию. Наиболее заметными причинами такой обструкции на этом уровне являются опухоли, врожденная этиология или поствоспалительная глиотическая атрезия.

Здесь мы представляем случай 65-летнего пациента с необычной симптоматической ЦВА, вызывающей стеноз и обструкцию синдвиева водопровода на уровне среднего мозга. Особенности этого случая обсуждаются вместе с его последствиями, включая распознавание, диагностику и лечение такой находки.

### Ключевые слова

акведукальный стеноз, венозная аномалия развития, гидроцефалия, МРТ, ЦВА