

Prosthetic Treatment of Cleft Lip and Palate Patient – a Case Report

Atanas Doshev¹, Vasko Doshev¹

¹ Department of Prosthetic Dentistry, Faculty of Dental Medicine, Medical University of Plovdiv, Plovdiv, Bulgaria

Corresponding author: Atanas Doshev, Department of Prosthetic Dentistry, Faculty of Dental Medicine, Medical University of Plovdiv, Plovdiv, Bulgaria; Email: nasko.doshev@yahoo.com; Tel.: +359 886 546 105

Received: 27 July 2021 ♦ **Accepted:** 6 Dec 2021 ♦ **Published:** 31 Aug 2022

Citation: Doshev A, Doshev V. Prosthetic treatment of cleft lip and palate patient – a case report. Folia Med (Plovdiv) 2022;64(4):697-700. doi: 10.3897/folmed.64.e72254.

Abstract

It is assumed that most cleft lip and palate are due to a combination of genetic and environmental factors (maternal diseases, smoking, alcohol intake, infections, and ionizing treatment) that alter morphogenesis. Treatment of these cases begins from birth to adulthood and requires a number of interventions depending on the period of development of the maxillofacial area and teeth.

We present the case of a patient with unilateral cleft lip and palate. Surgery and orthodontic treatment were carried out subsequently, and then a metal-ceramic bridge was made to correct the defect. In the course of the treatment, we made decisions that were determined by the available space.

The construction restored the dentition, the aesthetics, speech, and masticatory functions of the patient. The treatment of such defects requires good collaboration between individual specialists in order to achieve optimally good results. We believe that in such cases of crucial importance is the contribution of a prosthetic dentistry expert since surgical and orthodontic treatments alone are insufficient to achieve complete recovery and rehabilitation of patients.

Keywords

bridge, cheilognathopalatoschisis, metal-ceramic

INTRODUCTION

Cleft lip and palate are one of the most common deformities in humans. It is assumed that most cleft lip and palate are due to a combination of genetic and environmental factors (maternal diseases, smoking, alcohol intake, infections, and ionizing treatment) that alter morphogenesis.^[1] Treatment of such cases might begin at infancy and last until adulthood requiring a number of interventions depending on the stage of development of the maxillofacial area and teeth.^[2]

Patients with congenital clefts suffer from many problems and potential complications, so their treatment requires the involvement of a large team of specialists, in-

cluding a surgeon, an orthodontist, a prosthodontist, and a speech therapist.^[3] The members of this interdisciplinary team should work in sync to achieve a common goal – restoring speech, function, and aesthetics.^[4] Without the adequate involvement of each individual specialist, this goal cannot be achieved.^[5]

After surgical and orthodontic treatment, it is necessary to carry out prosthetic rehabilitation due to missing teeth, hypoplasia, malocclusion, and palatal defects. A subsequent prosthetic treatment serves to stabilize the result achieved and restore functional and aesthetic disturbances.^[6]

CASE REPORT

Patient I.B., 18 years old, had a congenital unilateral cleft lip and palate – cheilognathopalatoschisis. Surgical treatment consisted of uranoplasty and cheiloplasty. The orthodontic treatment corrected skeletal relationships, arranged teeth in the dentition, and provided space to restore the missing teeth. It was performed using a fixed technique due to the hypodontia in tooth 22, an impacted tooth 23, and progeny. When we attempted traction of tooth 23, it fractured and was subsequently extracted.

As a result of the orthodontic treatment, place was created on the left side, but unfortunately, it was not enough to restore both missing teeth 22 and 23, and it was wider for just one of them – 22. This was the maximum possible tooth position and there was no way this space to be bigger and to ensure full symmetry with the right side (Figs 1, 2).

For this reason, a multidisciplinary approach was needed in order to restore symmetry, aesthetics, speech, and masticatory function through prosthetic treatment with proper preparation and restoration. In general, patients under the

age of 20 are recommended to avoid non-removable prosthesis so as not to hinder the still incomplete bone development in the maxillofacial area. However, in patients with such cleft defects, there is a transverse maxillary deficiency due to the lack of mid-palatal suture.

In addition, there was an iatrogenic effect in this case of unsuccessful palatoplasty. As a result, growth in such a patient could not be expected. Besides, we should not underestimate the fact that after years of treatment, which begins after birth, patients insist on having a more modern treatment to improve not only the aesthetics, but also their psycho-emotional state and their integration into society.

The diagnosis in the present case was *adentia partialis maxillae* 22, 23. There were several possible treatments. In this case, we chose a metal-ceramic bridge – the pontic was a lateral incisor and the abutment teeth were teeth 12, 11, 21, 24, and 25. If we prepared only two teeth (for example 21 and 24), they could not absorb the masticatory pressure and would be overloaded. In addition, in the construction of a three-member bridge, the wider space only for tooth 22 could not be compensated and it must be modelled much larger than the analogous tooth 12.

In the frontal area, symmetry and aesthetics are always important, and therefore, with the patient's consent, teeth 12 and 11 were prepared. Tooth 24 was shaped to look like a canine, and tooth 25 was prepared to balance the construction, to redistribute the masticatory pressure and to compensate the lack of bone in the area of the cleft. It was precisely because of this lack of bone that implant treatment was impossible.

The treatment started with a primary impression from the upper jaw for the fabrication of a study model. Wax up was made from which a new impression was taken in order to make the temporary crowns.

This restored the symmetry and aesthetics of the frontal area without interfering with the future function. The teeth were prepared with a vestibular 1.2-mm chamfer finishing line, and a lingual 0.6-mm chamfer finishing line for the metal-ceramic bridge (Fig. 3).

After packing the retraction cords, impression was taken with a metal tray from the upper-jaw with an additive silicone (Fig. 4)

The impression from the lower jaw was taken with an alginate class A. To record the relationship between the upper

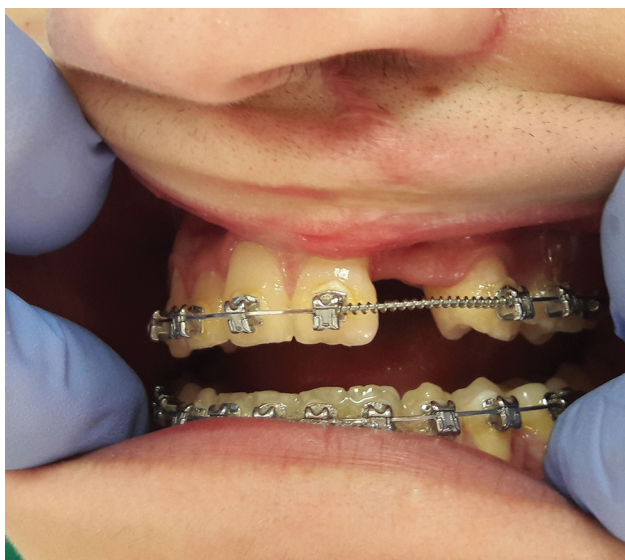

Figure 1. The space between teeth 21 and 24 after the orthodontic treatment.

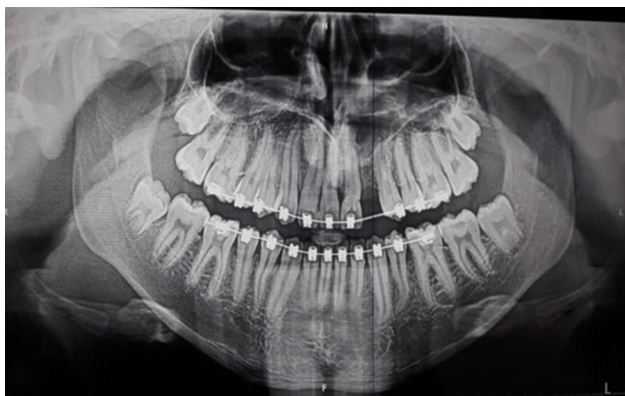


Figure 2. Panoramic X-ray of the patient.

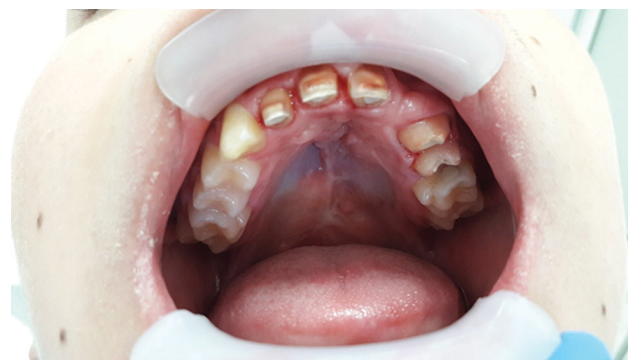

Figure 3. Teeth preparation.



Figure 4. Upper jaw impression.

and lower jaws in the central occlusion, a bite registration was taken with a C-silicone. After that a temporary restoration was made directly in the dental office using Protemp II (3M ESPE, USA). It was cemented using temporary cement until the permanent construction was ready. After the final restoration was made in the dental laboratory, it was adjusted and cemented in the patient's mouth (Figs 5, 6).

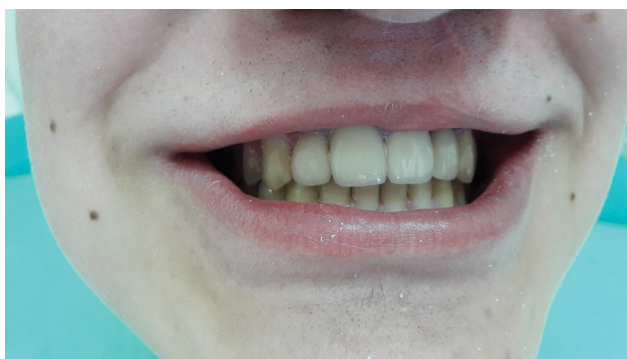

Figure 5. The final cemented prosthetic construction.

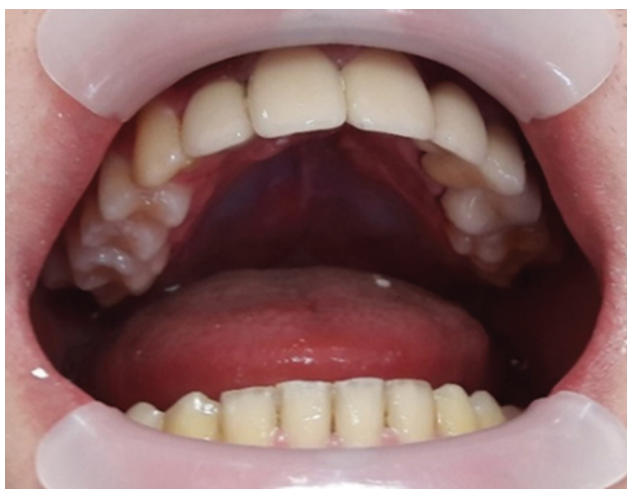

Figure 6. The final construction.

DISCUSSION

The final restoration fully met the patient's expectations. It restored the dentition, the aesthetics, speech, and masticatory function.

CONCLUSIONS

Surgical and orthodontic treatments alone are not enough for complete recovery and rehabilitation of the patient so the contribution of a specialist in prosthetic dentistry is important. The proposed method can serve as a treatment option.

REFERENCES

1. Atanasov D. Oral Surgery. Plovdiv. 2011; 884–5.
2. Madahar A, Murray A, Orr R, et al. The long and winding road – the journey of a cleft lip and palate patient part 1. Dent Update 2013; 40(10):791–4, 796–8.
3. Robin NH, Baty H, Franklin J, et al. The multidisciplinary evaluation and management of cleft lip and palate. South Med J 2006; 99(10):1111–20.
4. Ma QL, Conley RS, Wu T, et al. Interdisciplinary treatment for an adult with a unilateral cleft lip and palate. Am J Orthod Dentofacial Orthop 2014; 146(2):238–48.
5. Thom AR. Modern management of the cleft lip and palate patient. Dent Update 1990; 17(10):402–8.
6. Radnai M, Kocsis A, Kocsis SG, et al. Prosthetic rehabilitation of cleft palate patients with fixed partial dentures. Fogorv Sz 2002; 95(4):163–7.

Протезирование пациента с расщелиной губы и нёба – клинический случай

Атанас Дошев¹, Васко Дошев¹

¹ Кафедра протетической дентальной медицины, Факультет дентальной медицины, Медицинский университет - Пловдив, Пловдив, Болгария

Адрес для корреспонденции: Атанас Дошев, Кафедра протетической дентальной медицины, Факультет дентальной медицины, Медицинский университет - Пловдив, Пловдив, Болгария ; Email: nasko.doshev@yahoo.com; Тел.: +359 886 546 105

Дата получения: 27 июля 2021 ♦ **Дата приемки:** 6 декабря 2021 ♦ **Дата публикации:** 31 августа 2022

Образец цитирования: Doshev A, Doshev V. Prosthetic treatment of cleft lip and palate patient – a case report. Folia Med (Plovdiv) 2022;64(4):697-700. doi: 10.3897/folmed.64.e72254.

Резюме

Предполагается, что в большинстве случаев расщелина губы и нёба возникает из-за сочетания генетических факторов и факторов окружающей среды (материнские заболевания, курение, употребление алкоголя, инфекции и ионизирующее лечение), которые изменяют морфогенез. Лечение этих случаев начинается с рождения до совершеннолетия и требует проведения ряда вмешательств в зависимости от периода развития челюстно-лицевой области и зубов.

Мы представляем случай пациента с односторонней расщелиной губы и нёба. В последующем было проведено хирургическое и ортодонтическое лечение, а затем изготовлен металлокерамический мостовидный протез для исправления дефекта. В ходе лечения мы принимали решения, которые определялись имеющимся пространством.

Конструкция восстановила зубной ряд, эстетику, речь и жевательные функции пациента. Лечение таких дефектов требует хорошего сотрудничества между отдельными специалистами для достижения оптимально хороших результатов. Мы считаем, что в таких случаях решающее значение имеет вклад специалиста в области протетической дентальной медицины, поскольку одних хирургических и ортодонтических методов лечения недостаточно для достижения полного выздоровления и реабилитации пациентов.

Ключевые слова

мостовидный протез, хейлогнатопалатосхизис, металлокерамический
